

Gyulladás patológiája I.

Dr. Tímár József



Gyulladás

Vaszkularizált élő szövet reakciója
a lokális sejt/szövetkárosodásra

Gyulladás okai

- Mikroorganizmusok (bacterium, gomba, virus)
- Zoonosis (féreg, protozoon, rovar)
- Toxikus anyag
- Mechanikus sérülés
- Hőhatás
- Radioaktivitás
- Endogen toxin (uraemia)
- Daganat
- Necrosis

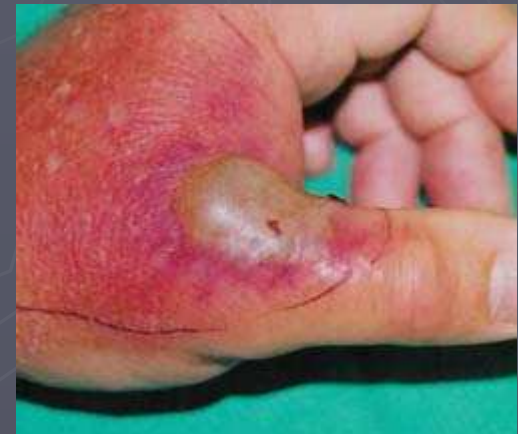Gyulladás szakaszai

- Acut
- Subacut
- Chronicus



A gyulladás fő jelei (GALENUS)

- Rubor
- Calor
- Dolor
- Tumor
- Functio laesa



Heveny gyulladás

- Vaszkuláris jelenségek
- Sejtszintű eltérések

Kiváltó ok

Vasoaktiv mediatorok:

- histamin
- serotonin
- bradykinin
- anaphylatoxin
- LT, PG, PAF

Gyulladásos mediátorok

Kemotaktikus faktorok:

- C5a
- LTB
- peptidek (formil)
- limfokinek
- monokinek

Permeabilitás fokozódás

Chemotaxis + gyulladásos sejtek aktiválódása

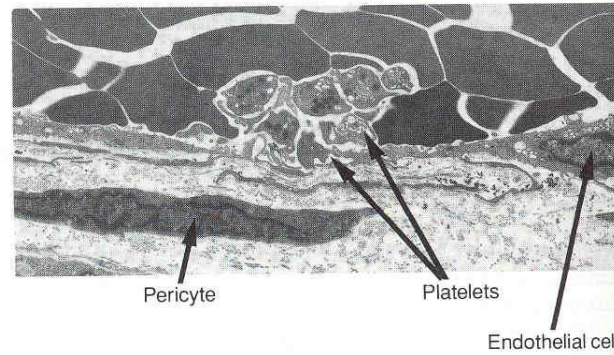
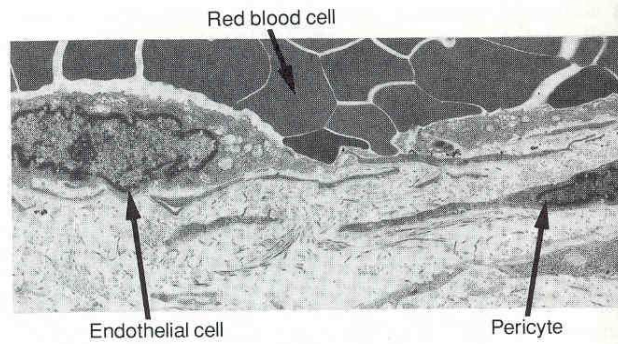
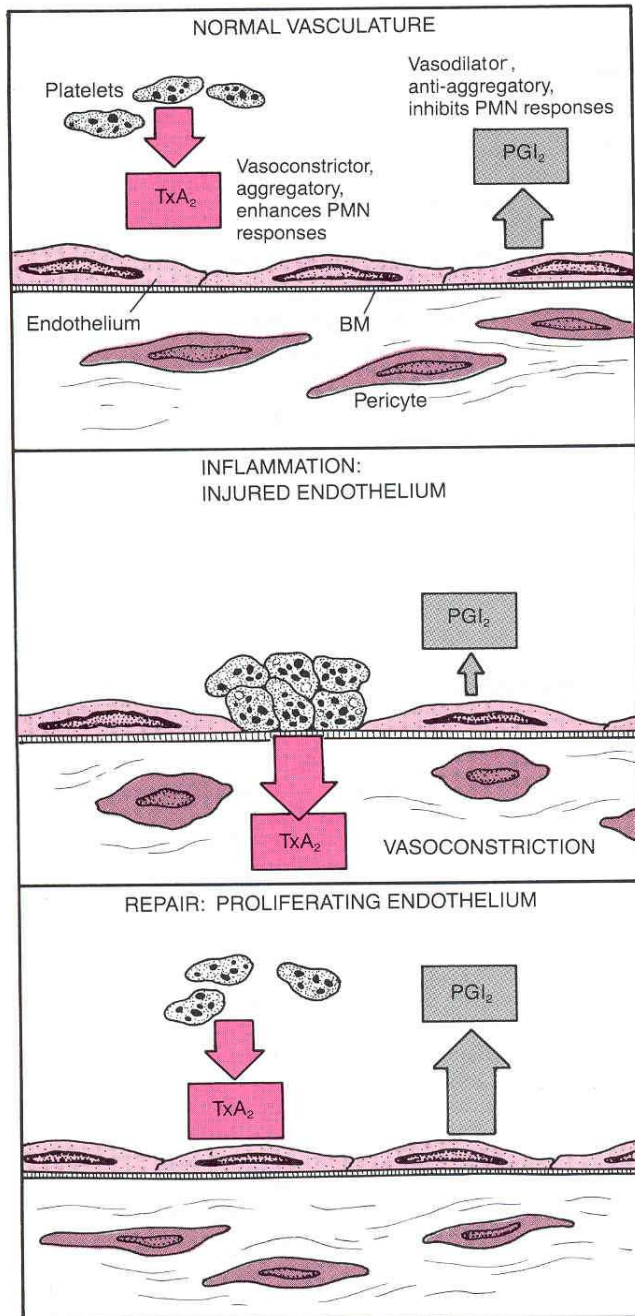
OEDEMA
(transsudatio: alacsony mólsúlyú
Fehérjék, folyadék...)

**ACUT
GYULLADÁS:**
-neutrofilek
-vérlemezke
-vvt

CHRONICUS gyulladás:
-makrofág
-limfocita
-plazmasejt

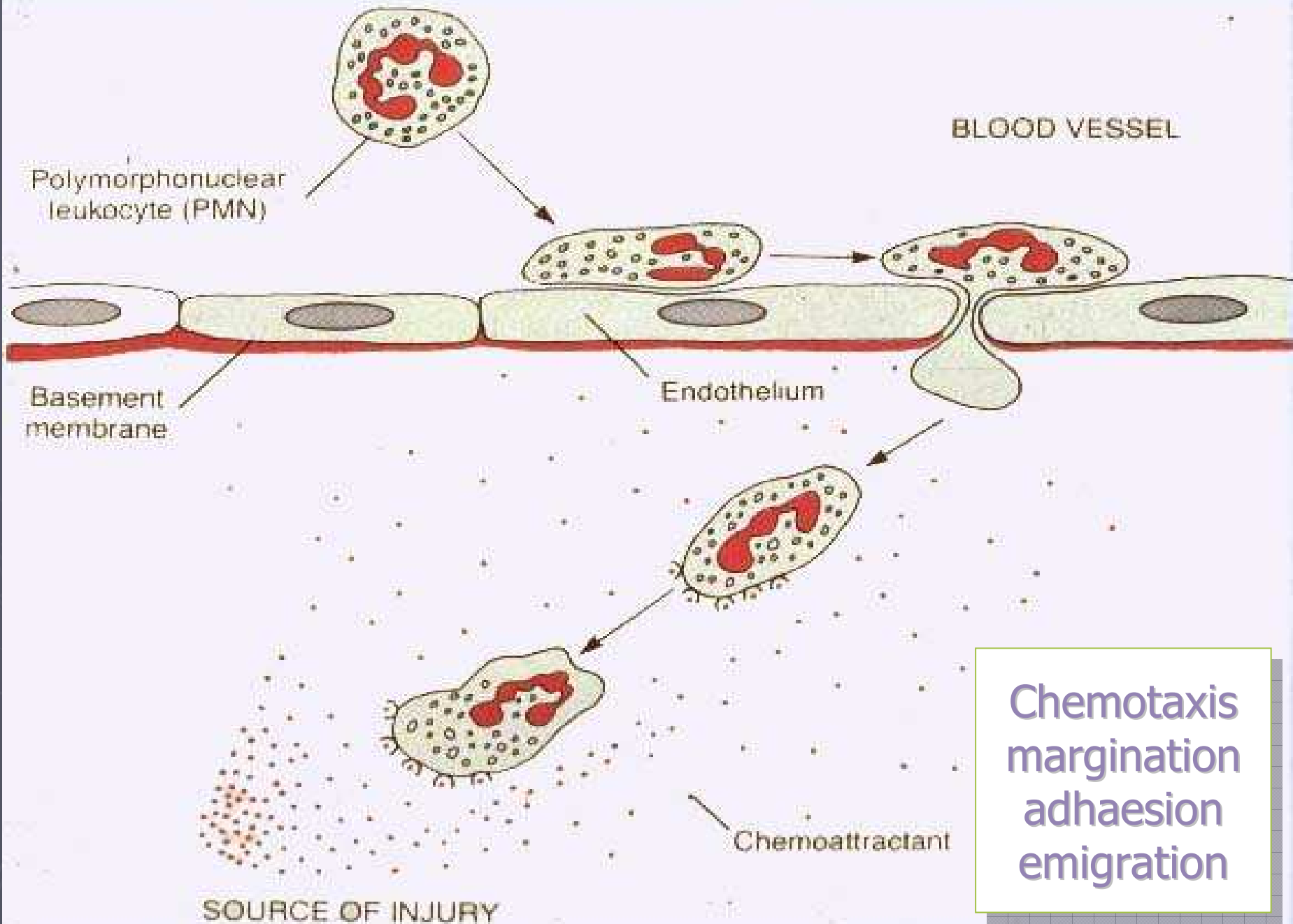
Az endotélsejtek szerepe

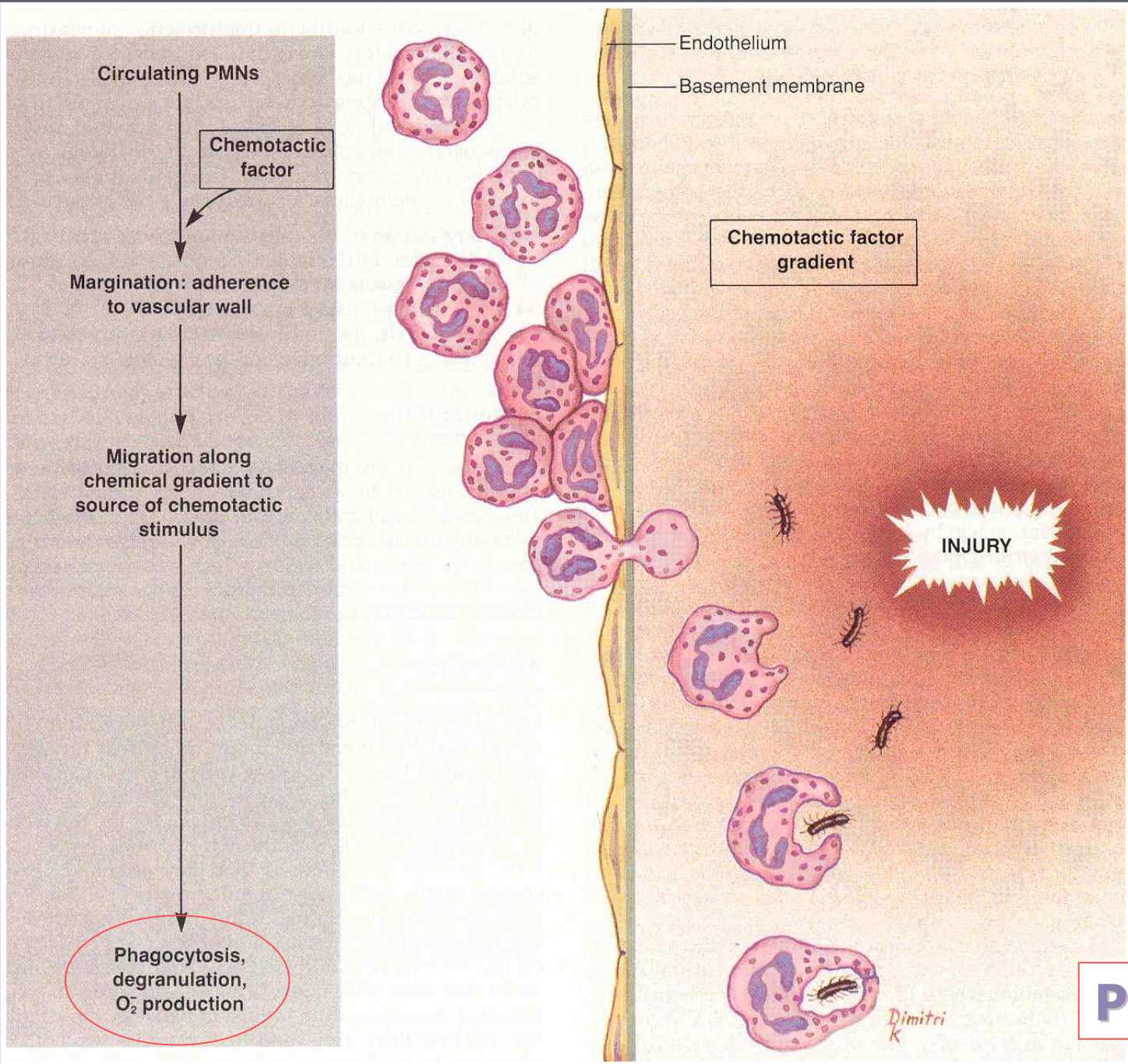
- **Permeabilitás szabályozása**
 - Sejtkapcsoló struktúrák (claudin5)
 - Vesicula
 - Transendotheliális csatorna (Weiber Pallade)
- **Metabolitok termelése**
 - PGI₂, Plasminogen activator uPA
 - VIII. factor, vW factor, ACE
 - EDRF, endothelin
 - Extracelluláris matrix (BM)
- **Anyagtranszport, lebontás**
 - Catecholaminok, vasoactive aminok, LDL



Rolling
Docking
Locking

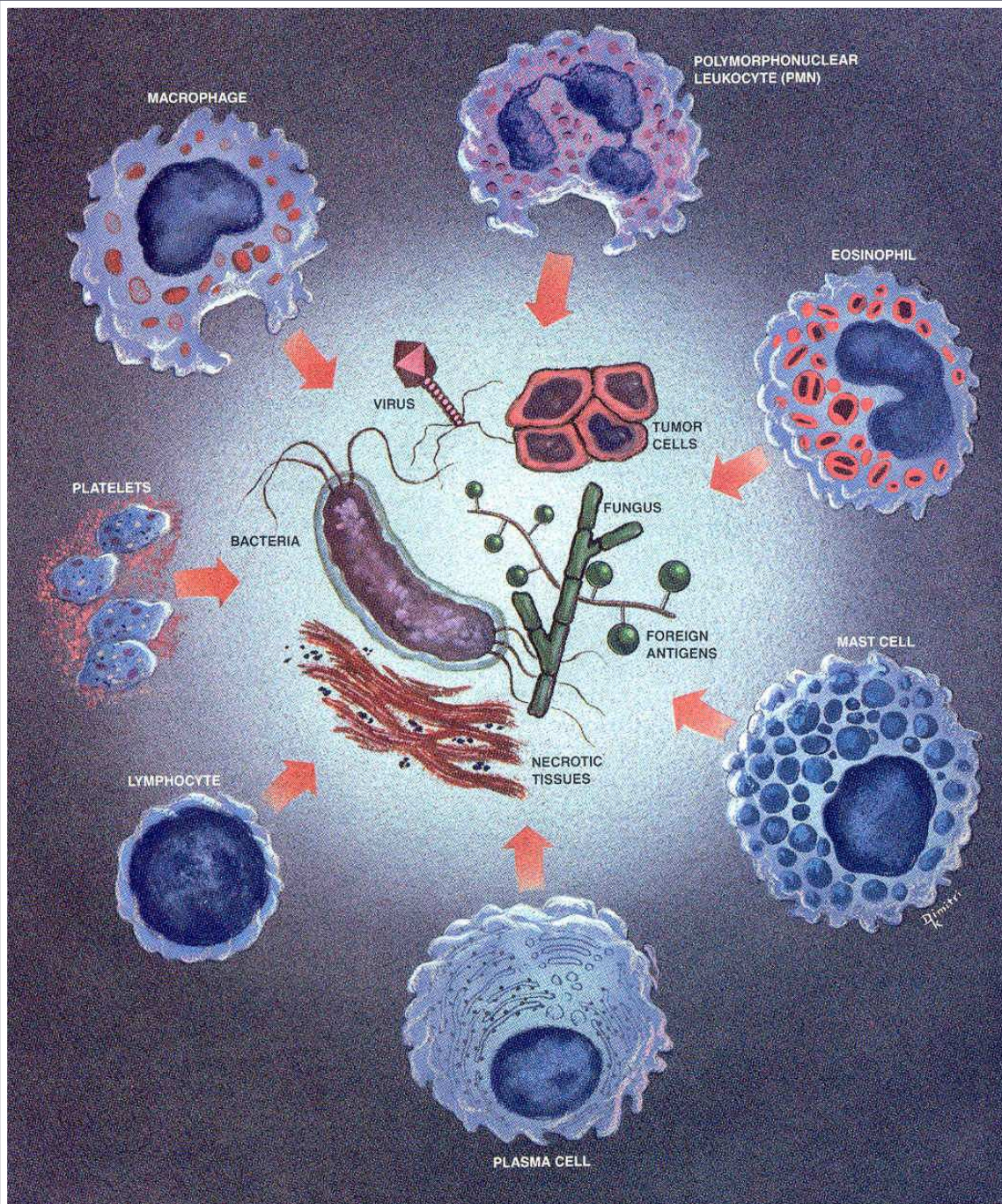
migration



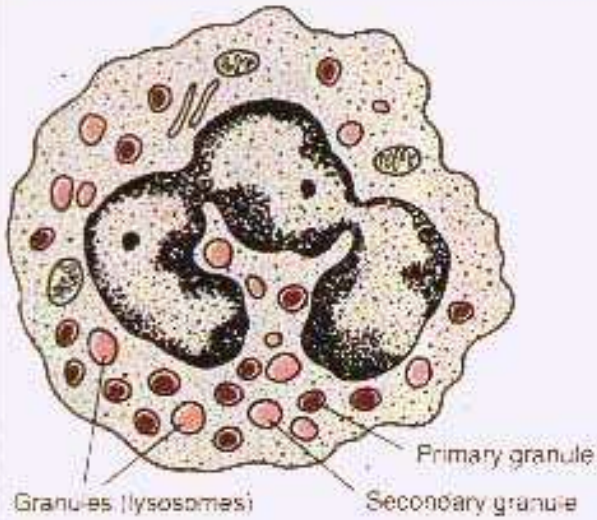


Phagocytosis

Dimitri K



Gyulladásos sejttípusok



CHARACTERISTICS AND FUNCTIONS

- Acute inflammation
- Bacterial and foreign body phagocytosis

PMN INFLAMMATORY MEDIATORS

- Reactive oxygen metabolites
- Lysosomal granule contents

-Primary granules

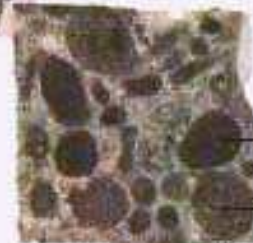
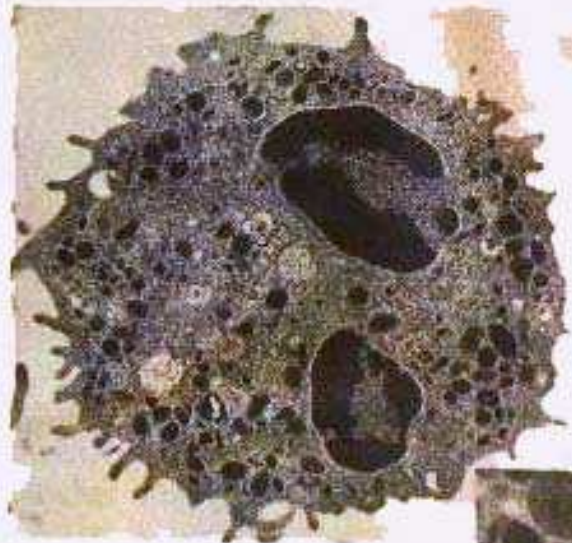
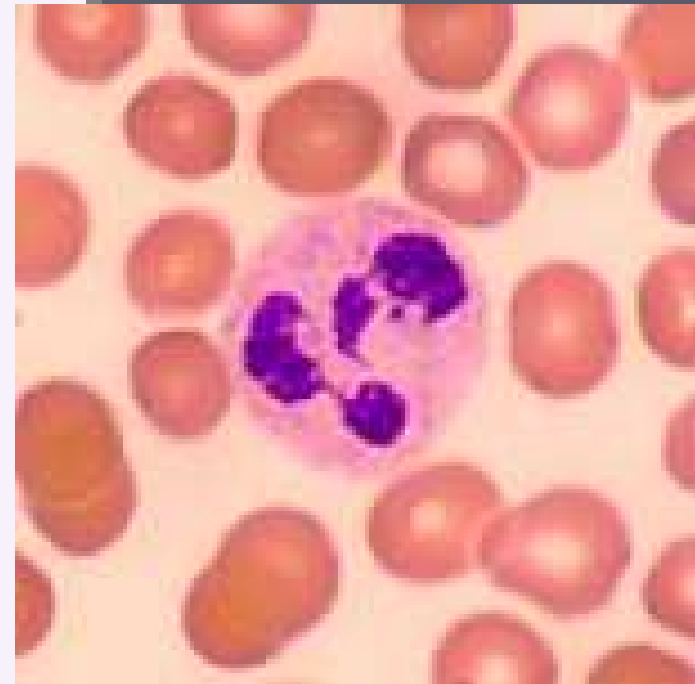- Phospholipase A₁
- Myeloperoxidase
- Lysozyme
- Cationic proteins
- Acid hydrolases
- Elastase
- Cathepsins

-Secondary granules

- Phospholipase A₂
- Lysozyme
- Alkaline phosphatase
- Collagenase
- Lactoferrin
- Vitamin B₁₂ binding proteins

-Tertiary or C particles

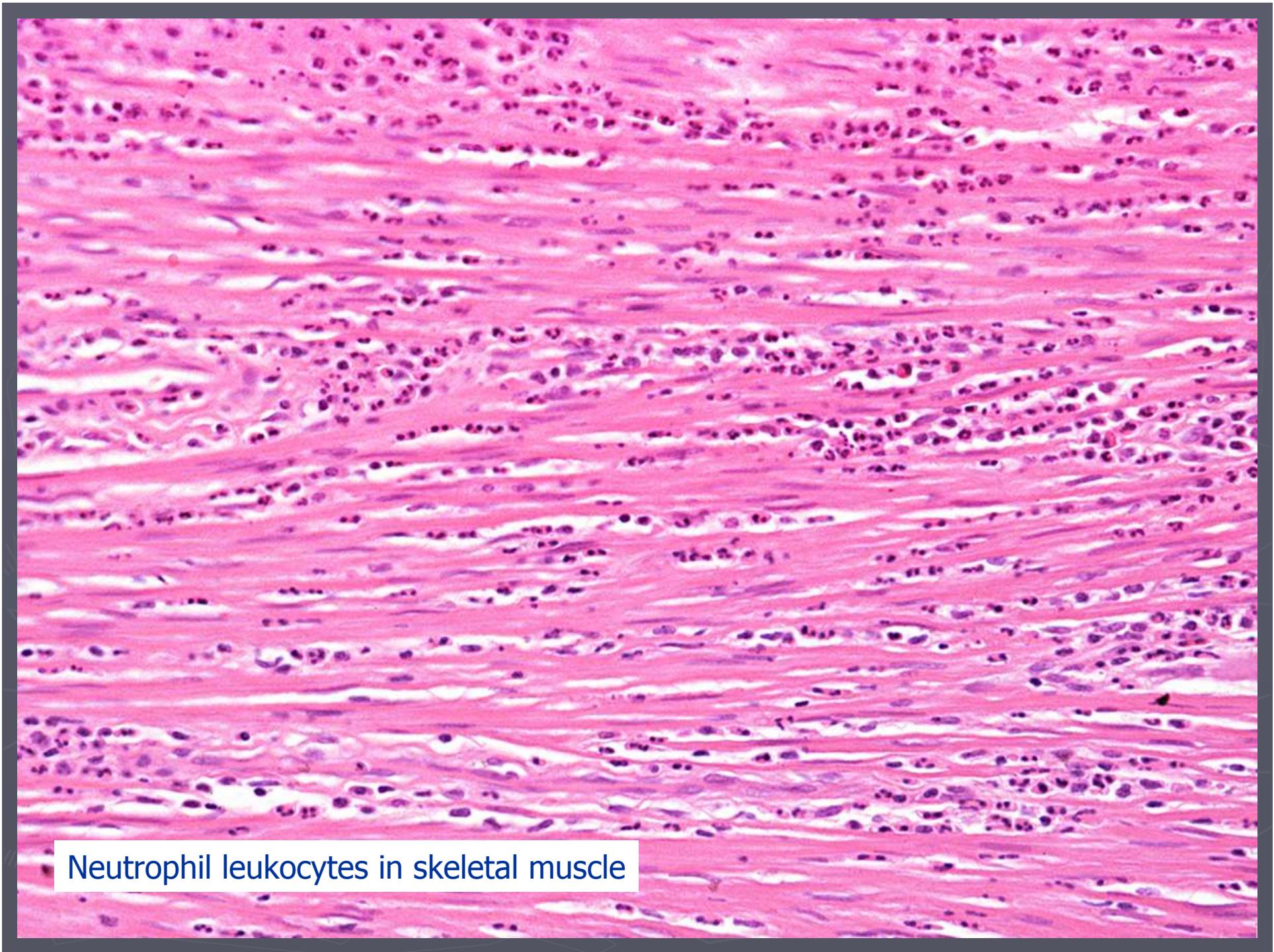
- Gelatinase
- Cathepsins



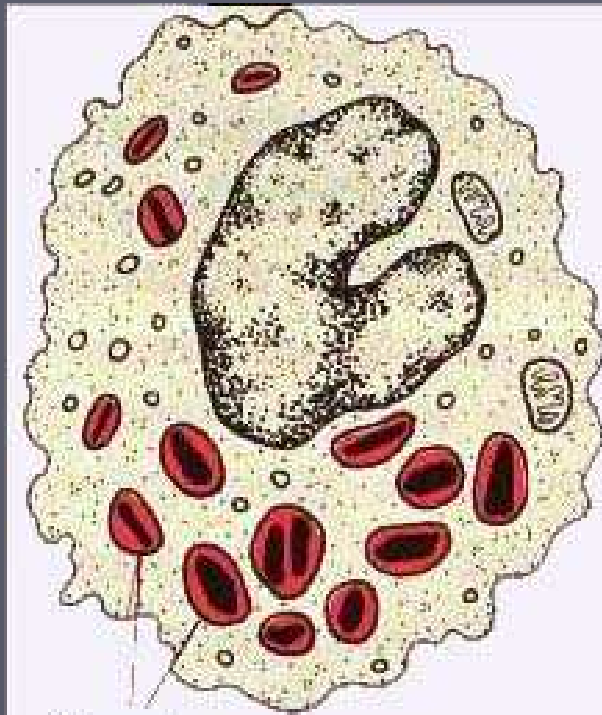
Primary granule

Secondary granule

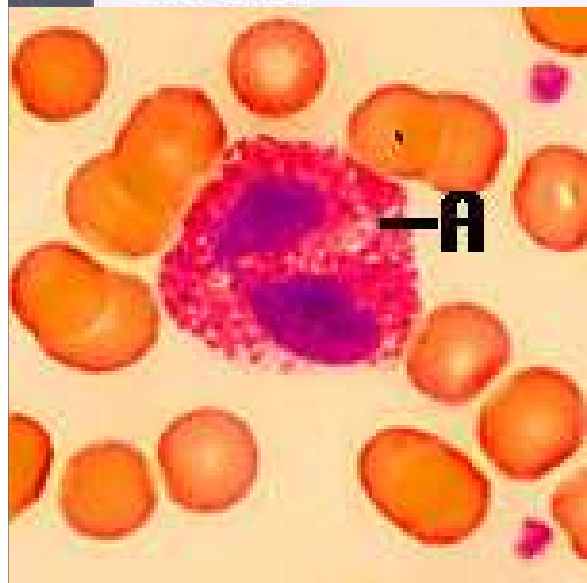
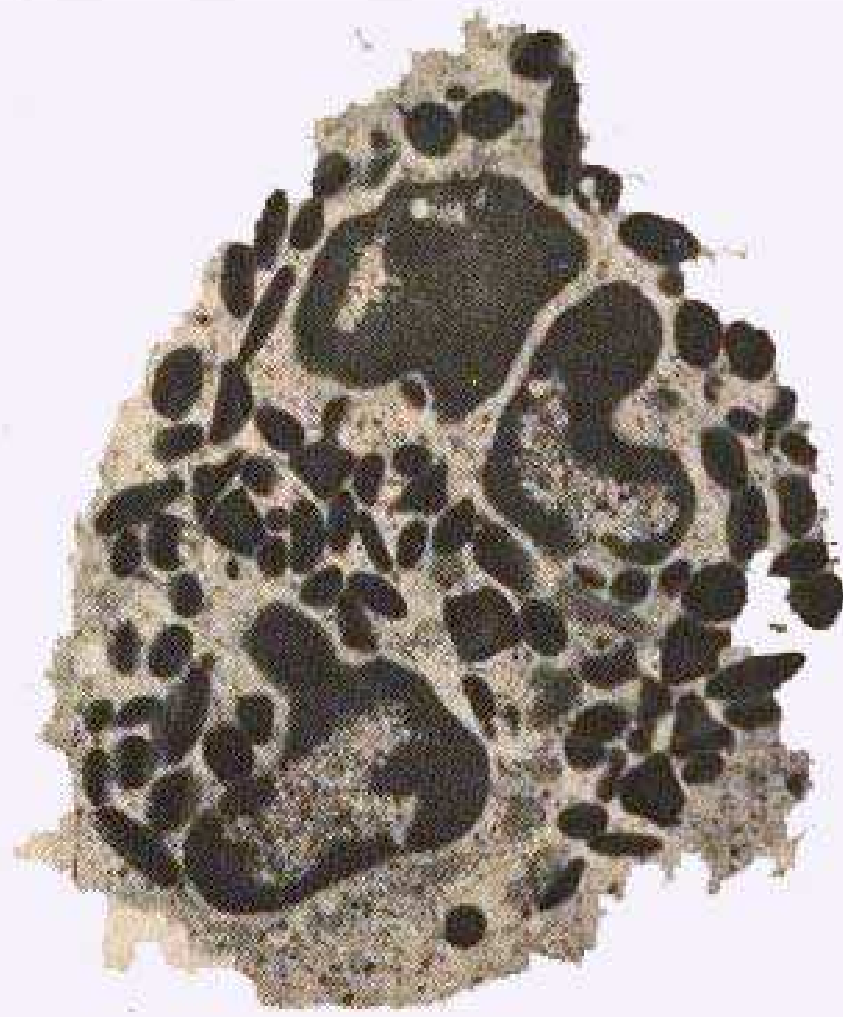Neutrophil granulocita



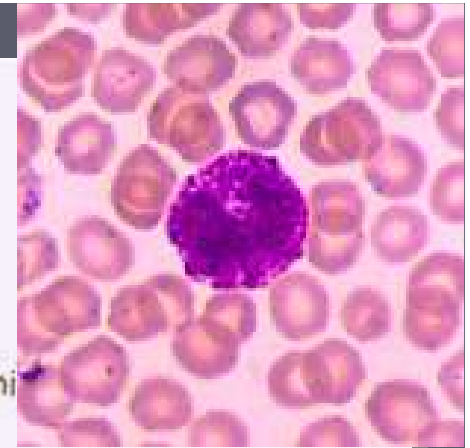
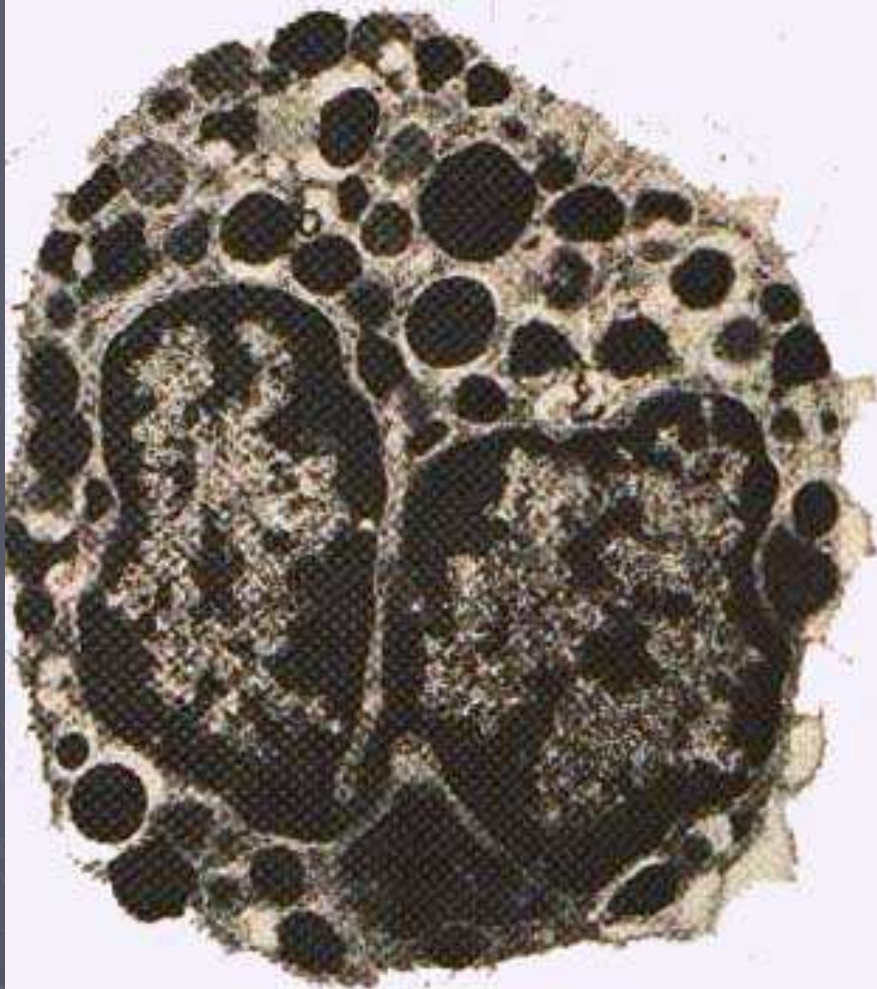
Neutrophil leukocytes in skeletal muscle



Granules



Eosinofil
granulocita



Mast Cell (Basophil)

CHARACTERISTICS AND FUNCTIONS

- Binds IgE molecules
- Contains electron-dense granules

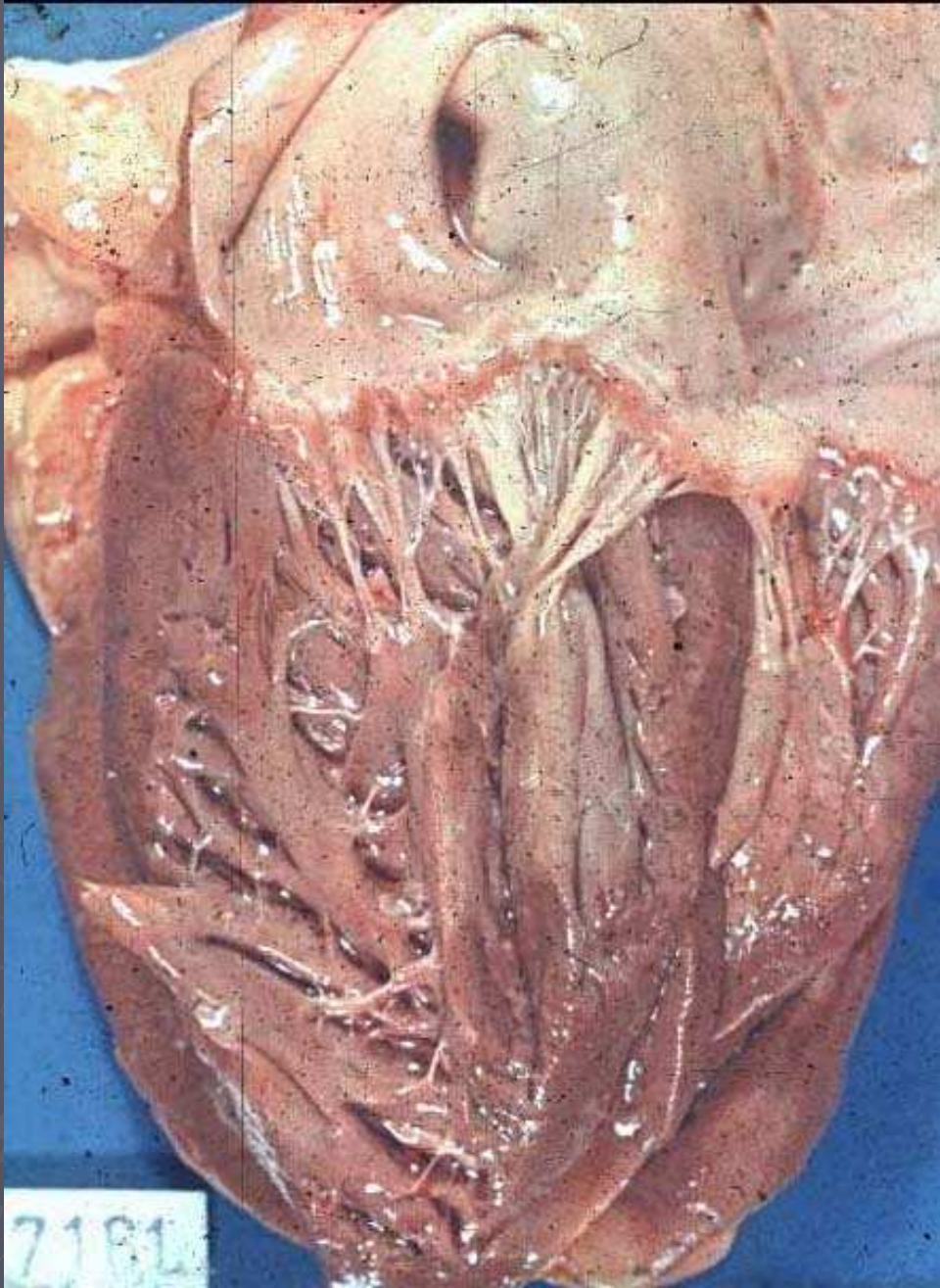
PRIMARY INFLAMMATORY MEDIATORS

- Histamine
- Leukotrienes (LTC₄, LTD₄, LTE₄)
- Platelet activating factor
- Eosinophil chemotactic factors

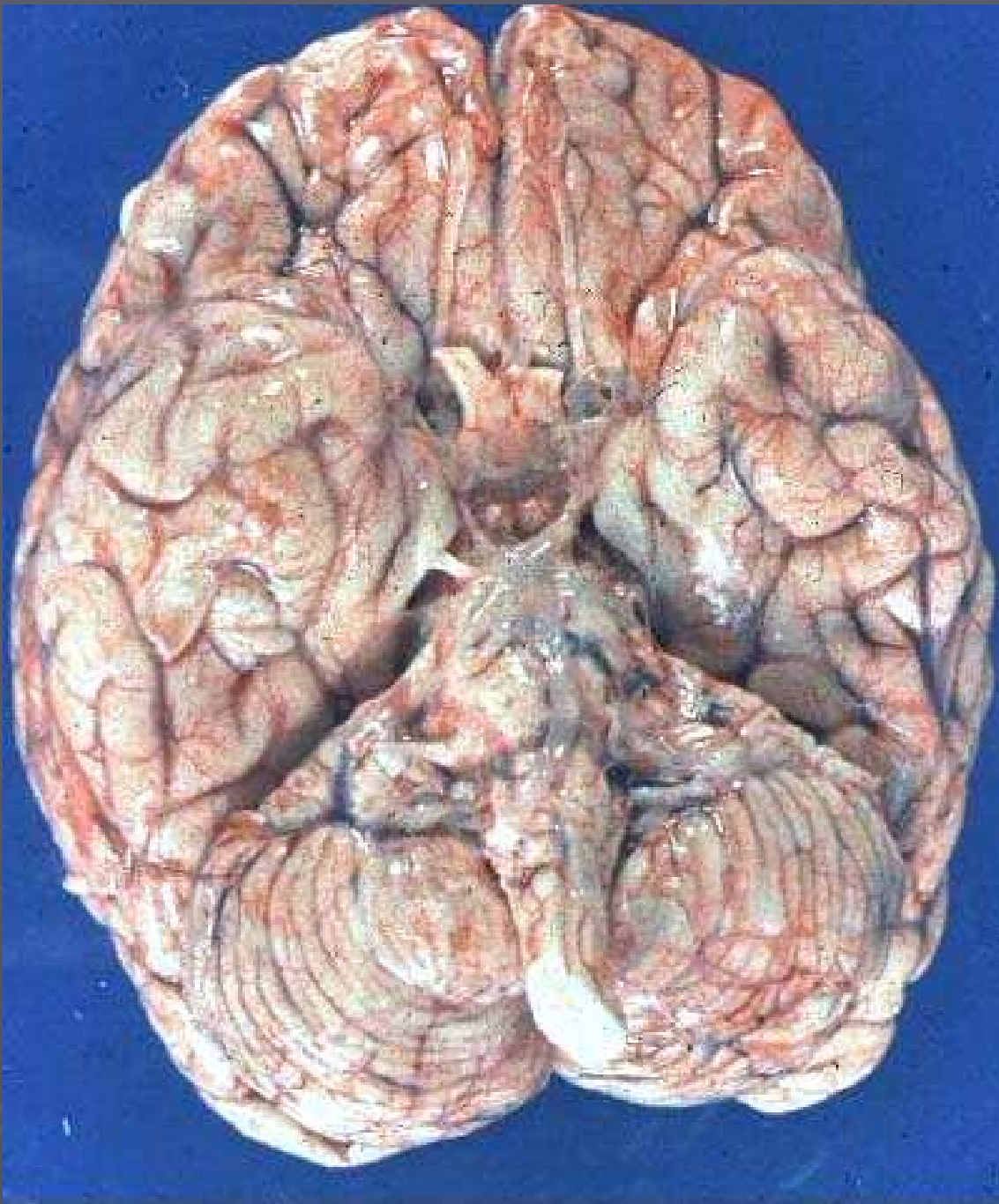
Mast cell (basophil granulocyte)

Acut gyulladás típusai az exsudatum alapján:

- Serosus – inflammatio serosa
- Fibrinosus – inflammatio fibrinosa
- Purulens – inflammatio purulenta
- Vérzéses – inflammatio haemorrhagica
- Gangrenozus – inflammatio ichorosa seu gangraenosa



Endocarditis
serosa

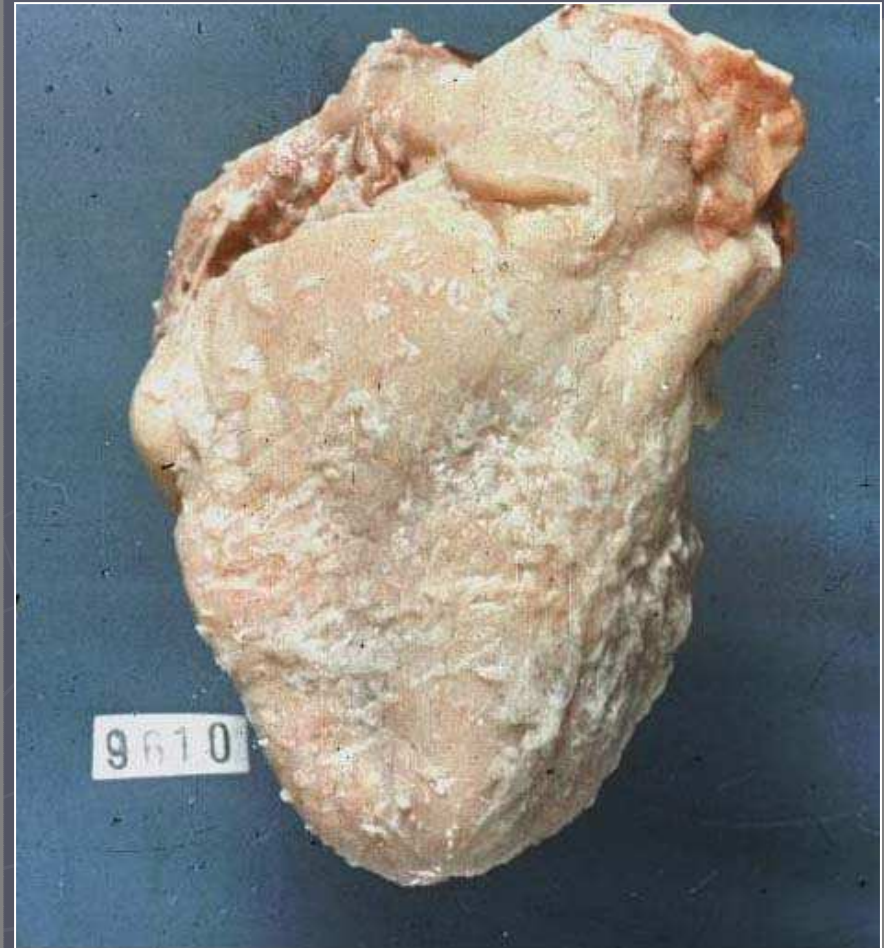
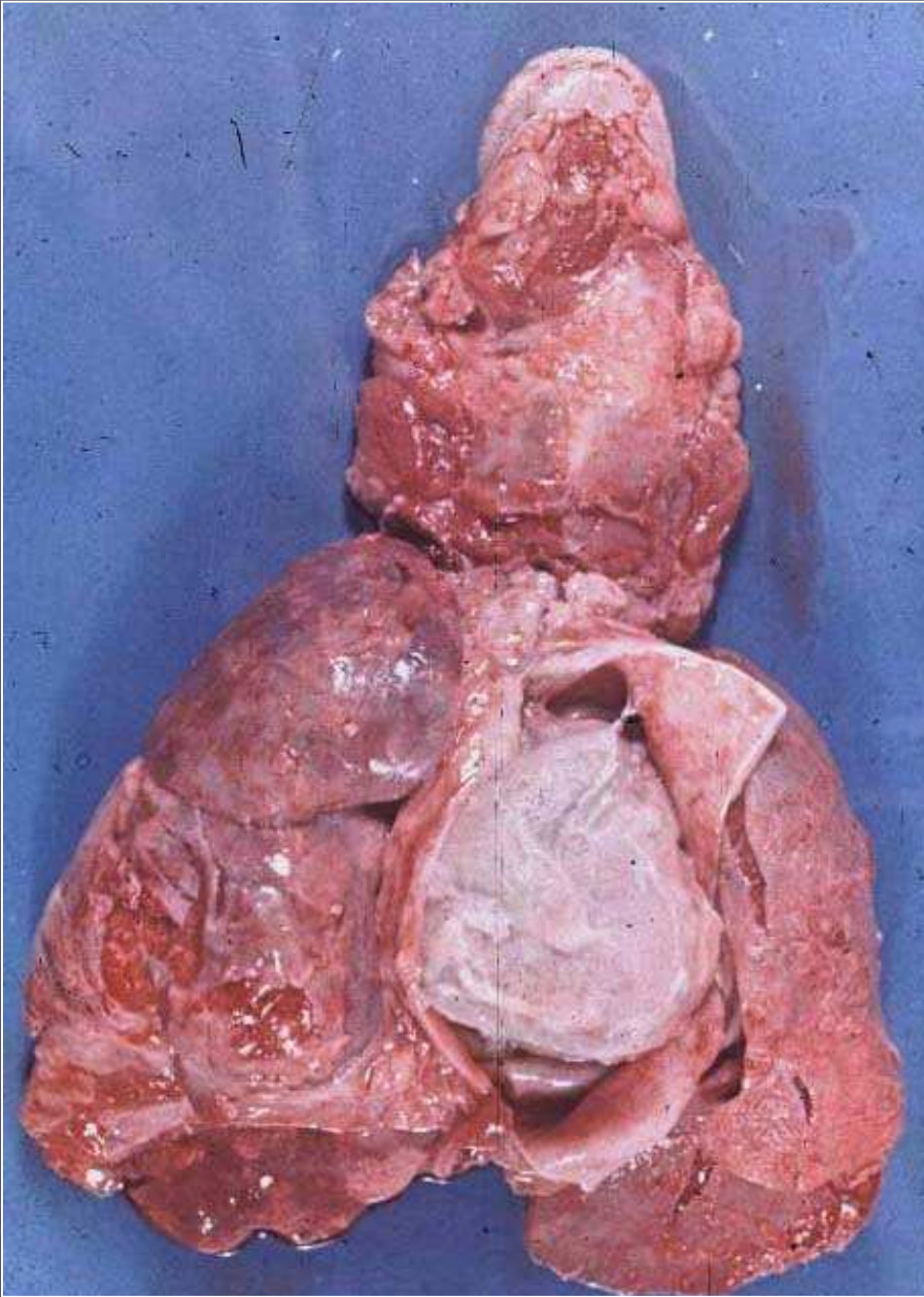


**Meningitis
serosa**

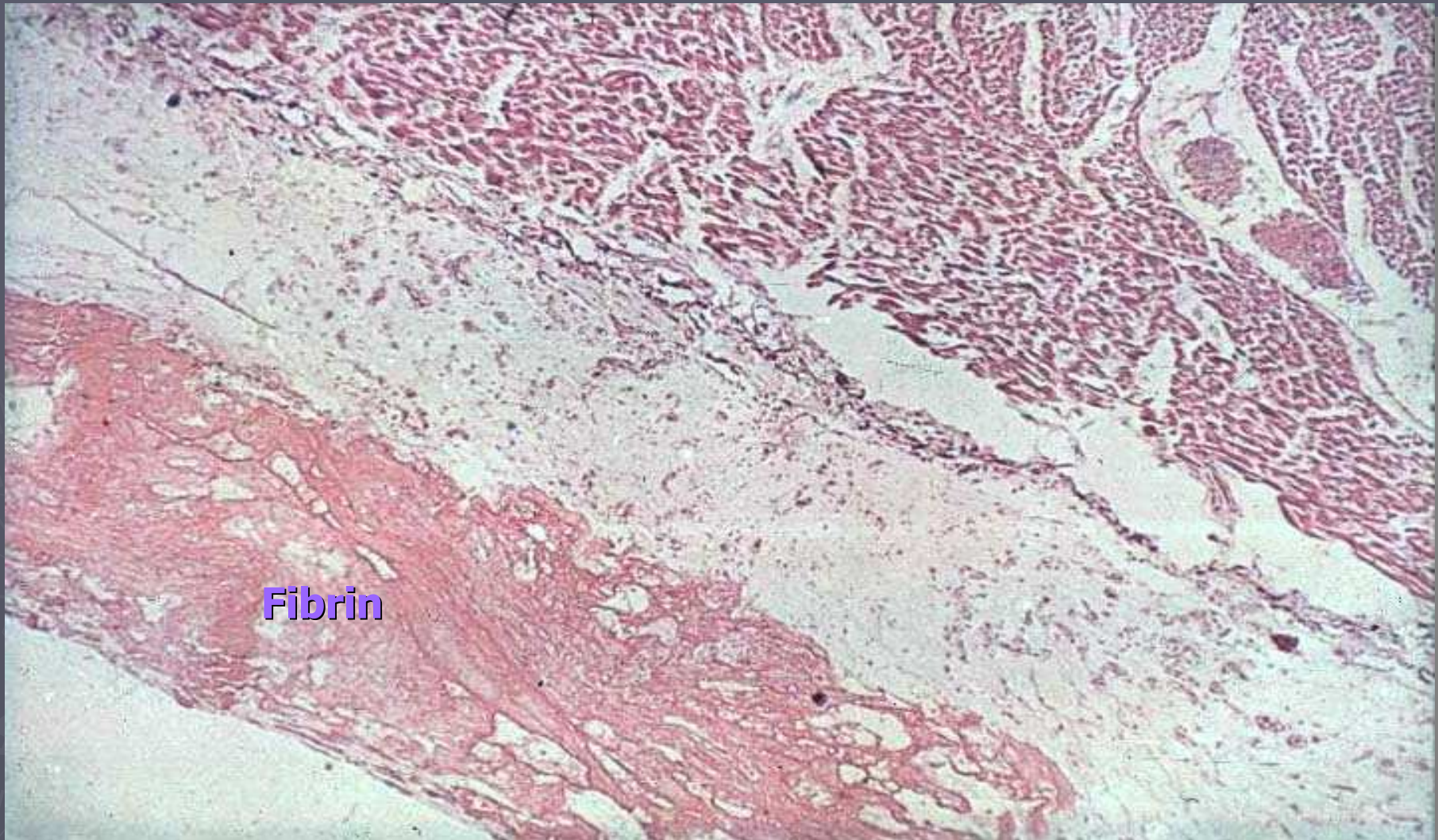
Acut gyulladás típusai az exsudatum alapján:

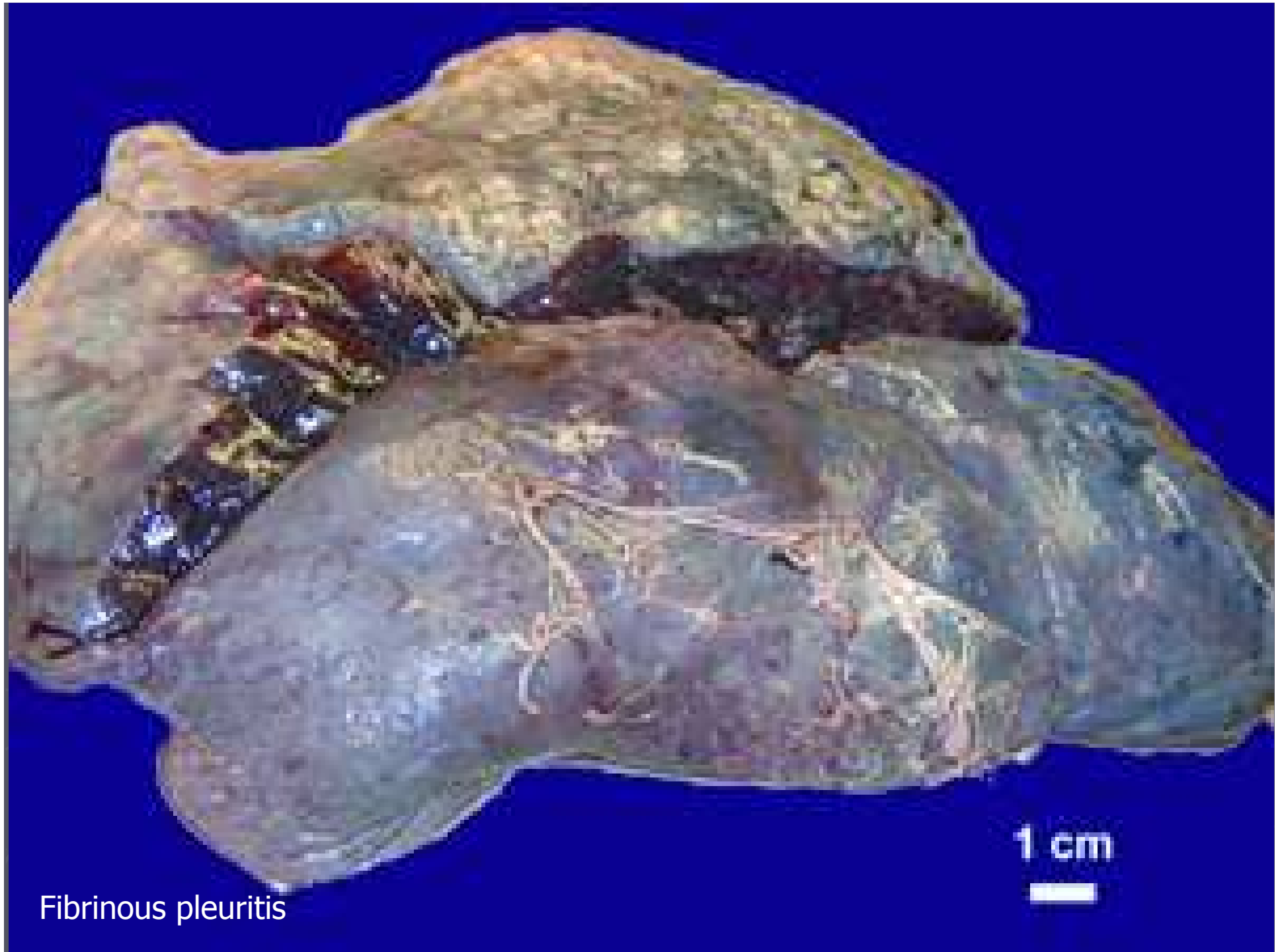- Serosus – inflammatio serosa
- **Fibrinosus – inflammatio fibrinosa**
- Purulens – inflammatio purulenta
- Vérzéses – inflammatio haemorrhagica
- Gangrenozus – inflammatio ichorosa seu gangraenosa

Pericarditis fibrinosa



Pericarditis fibrinosa (H&E)



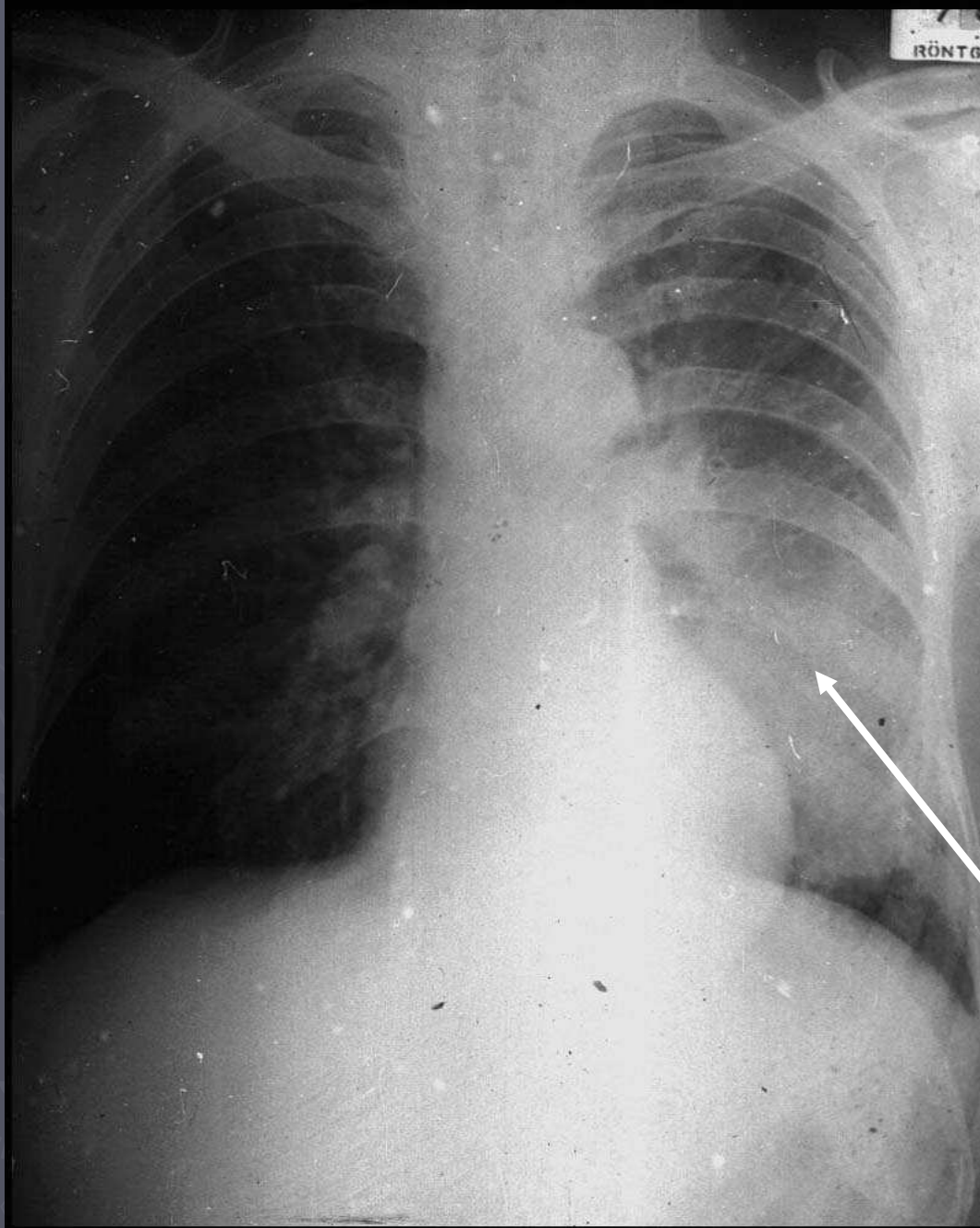


Fibrinous pleuritis

1 cm

A gross pathology specimen showing fibrinous peritonitis. The image displays several large, irregular, yellowish-tan, gelatinous masses of fibrin that have adhered to the underlying tissue. The surrounding tissue is a reddish-brown color, likely representing the underlying organ or mesentery. The fibrin has a characteristic web-like or clotted appearance, typical of an acute inflammatory response in the peritoneum.

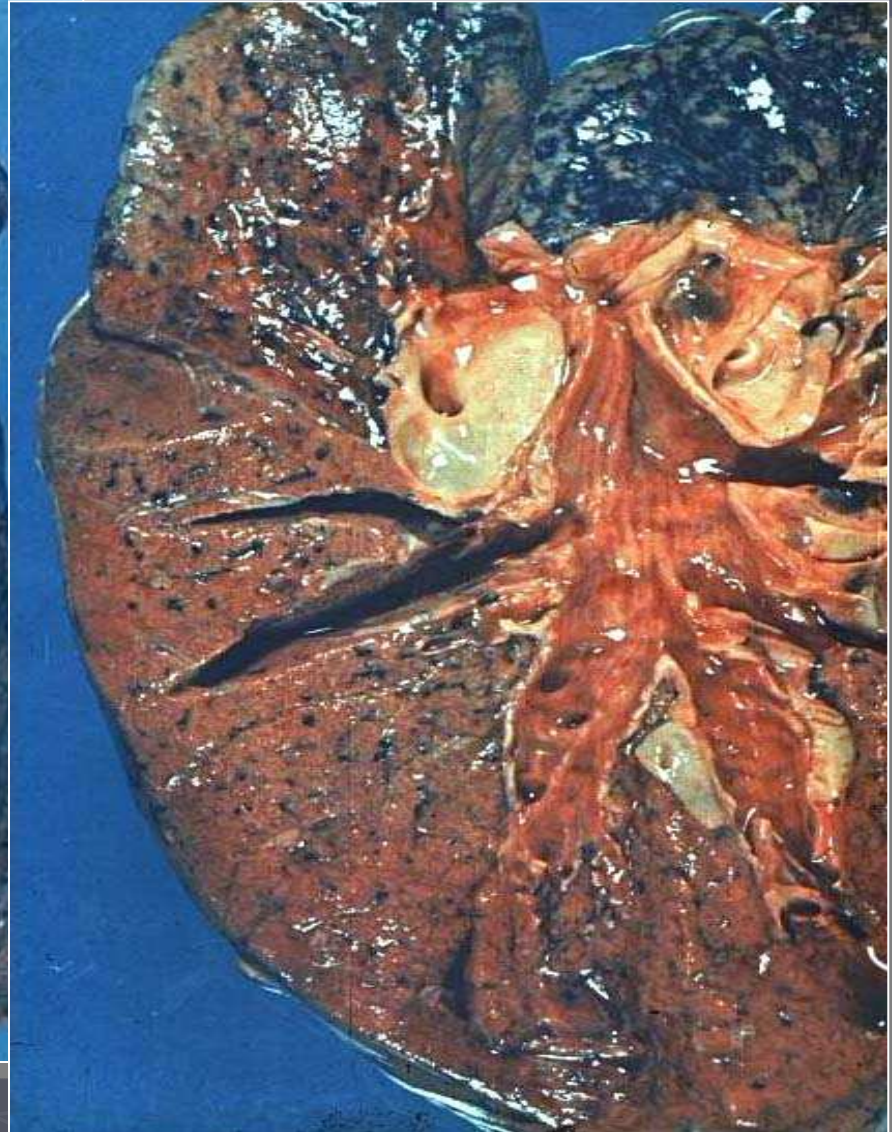
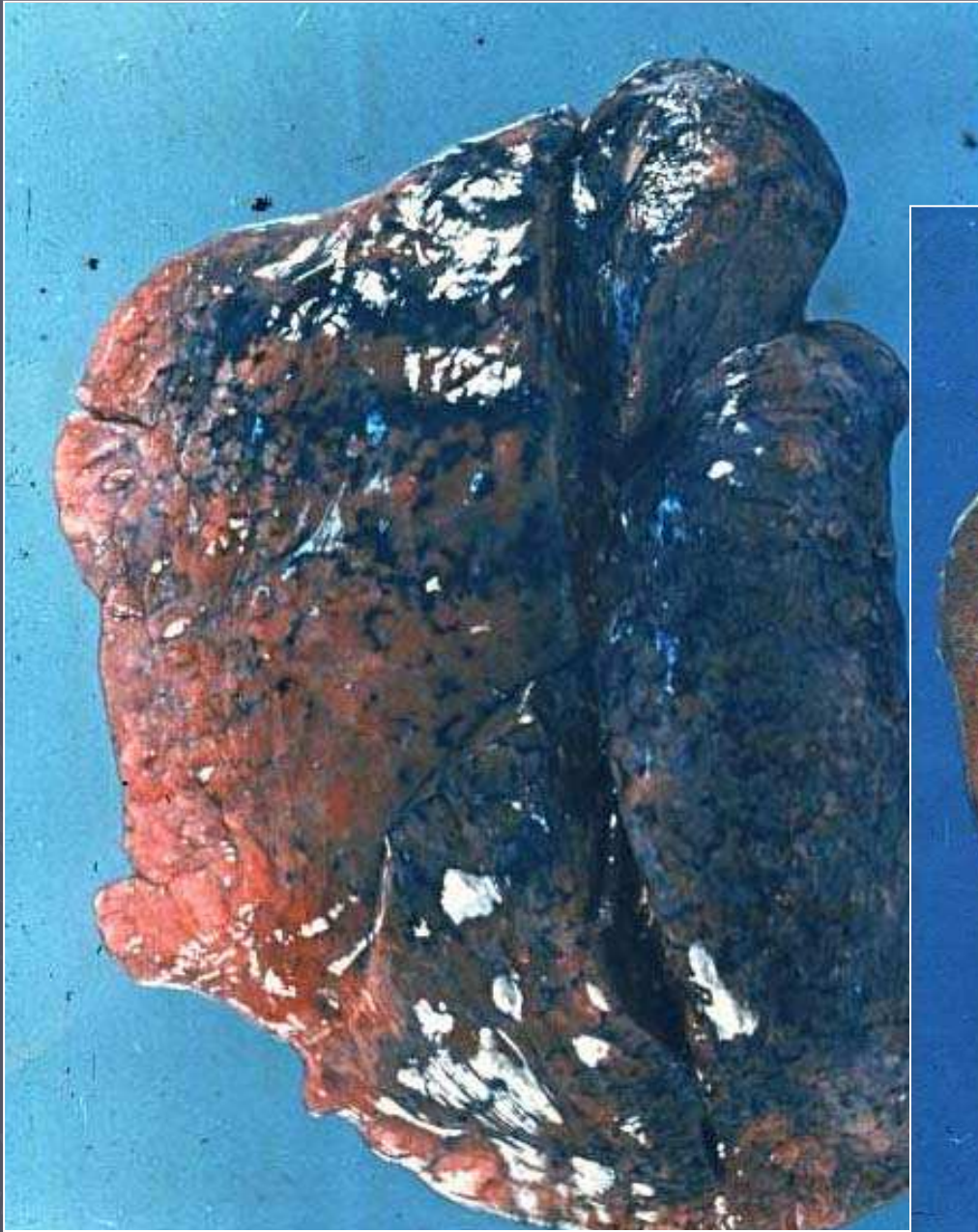Fibrinous peritonitis

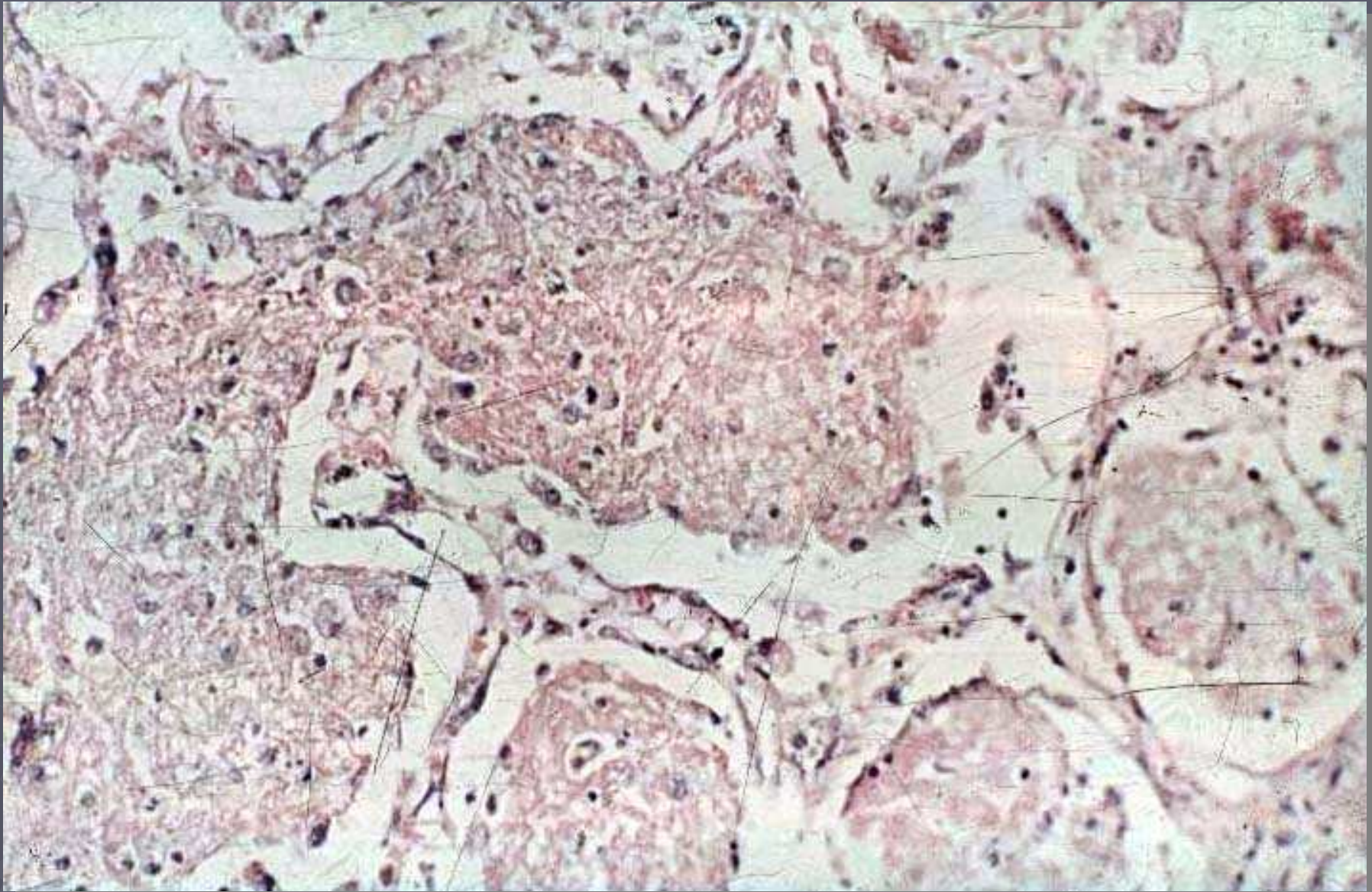


Lobaris
pneumonia

RTG

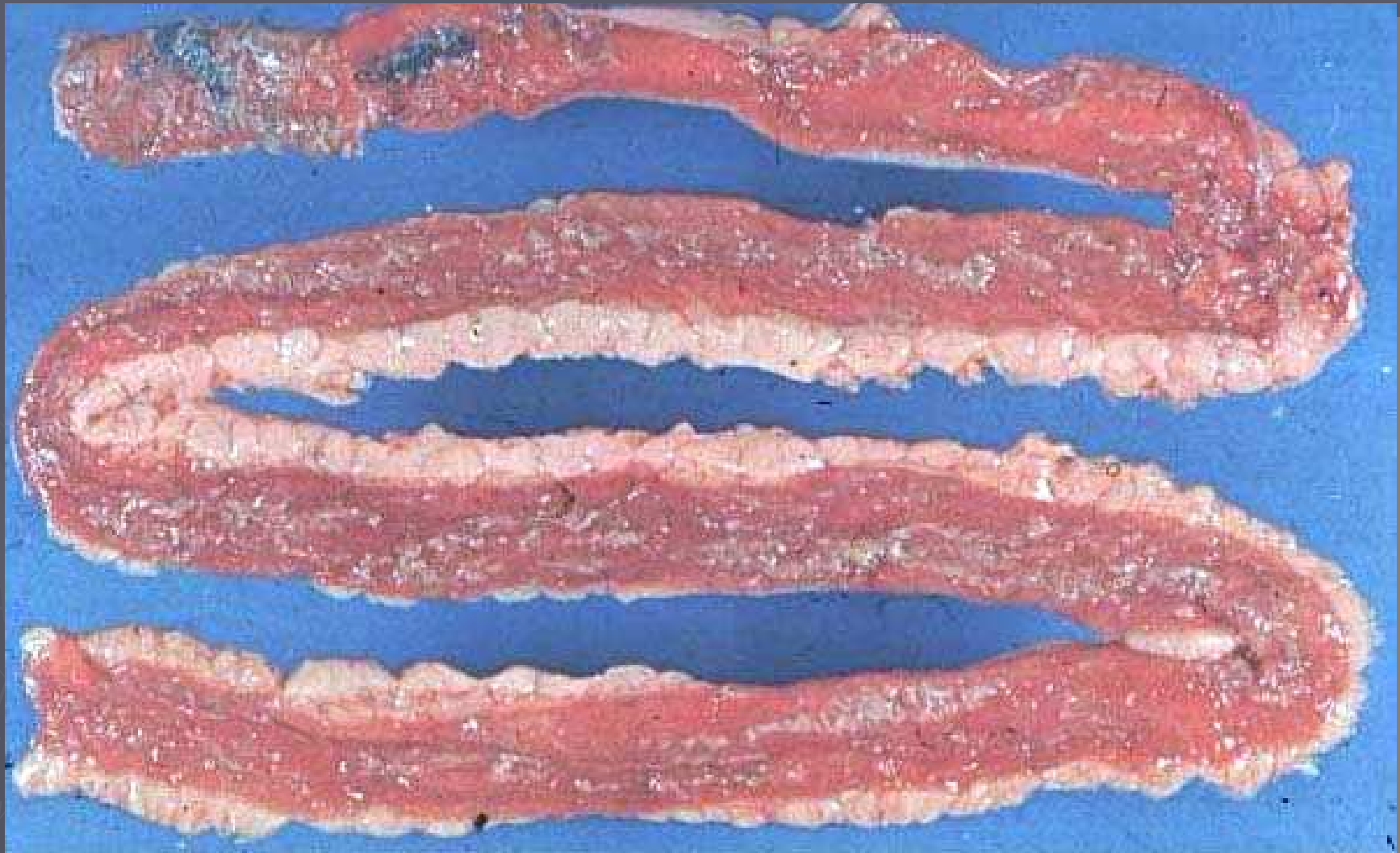
Lobaris pneumonia



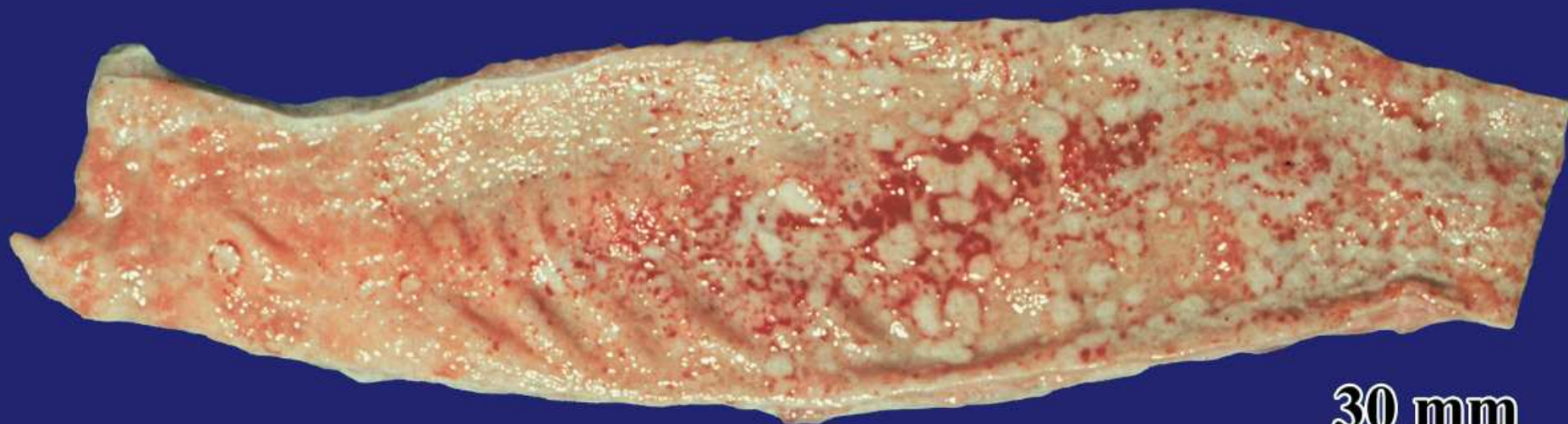


Lobaris pneumonia (H&E)

Pseudomembranozus bélgyulladás



Dysentery (fibrinopurulens vastagbélgyulladás)

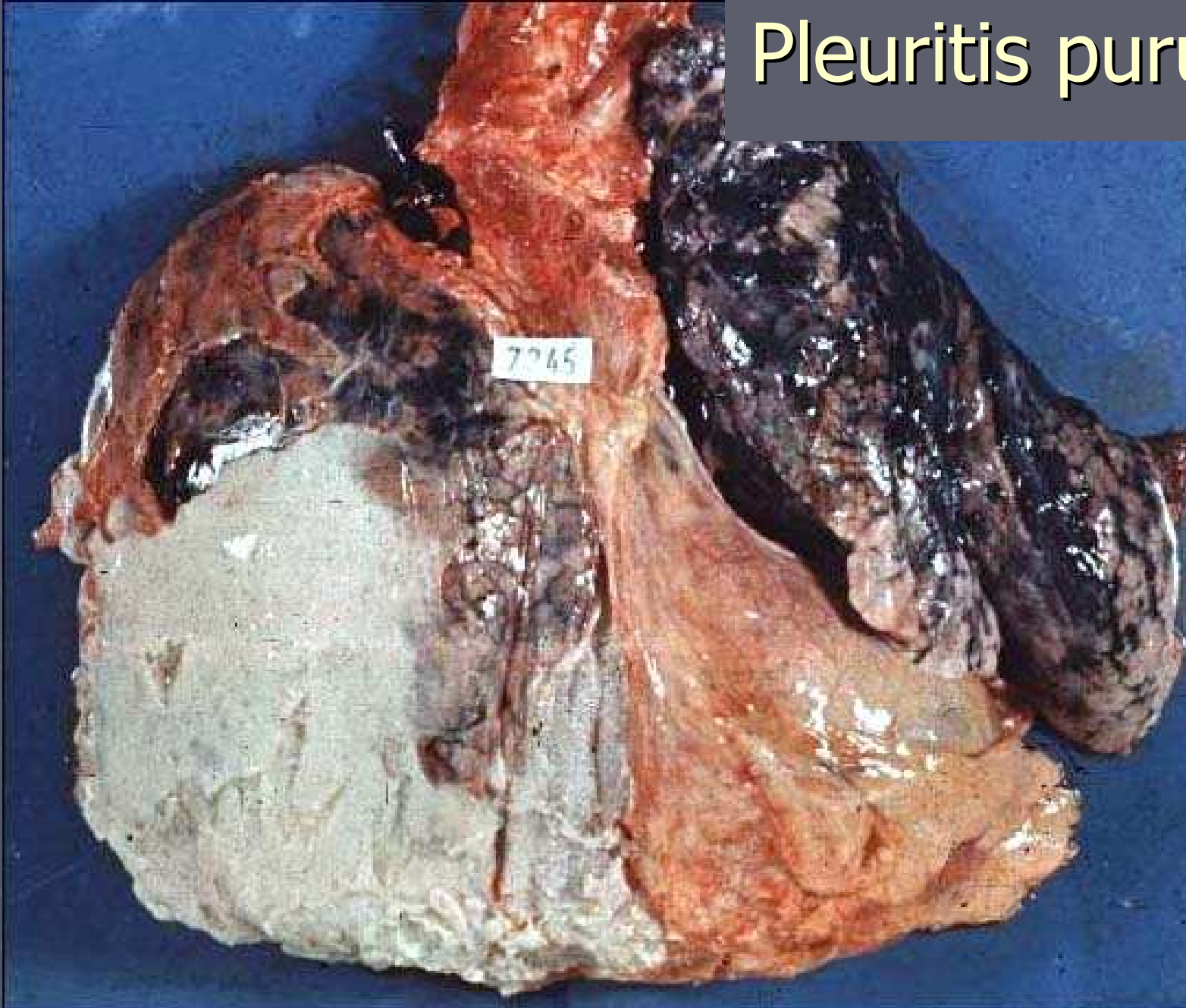


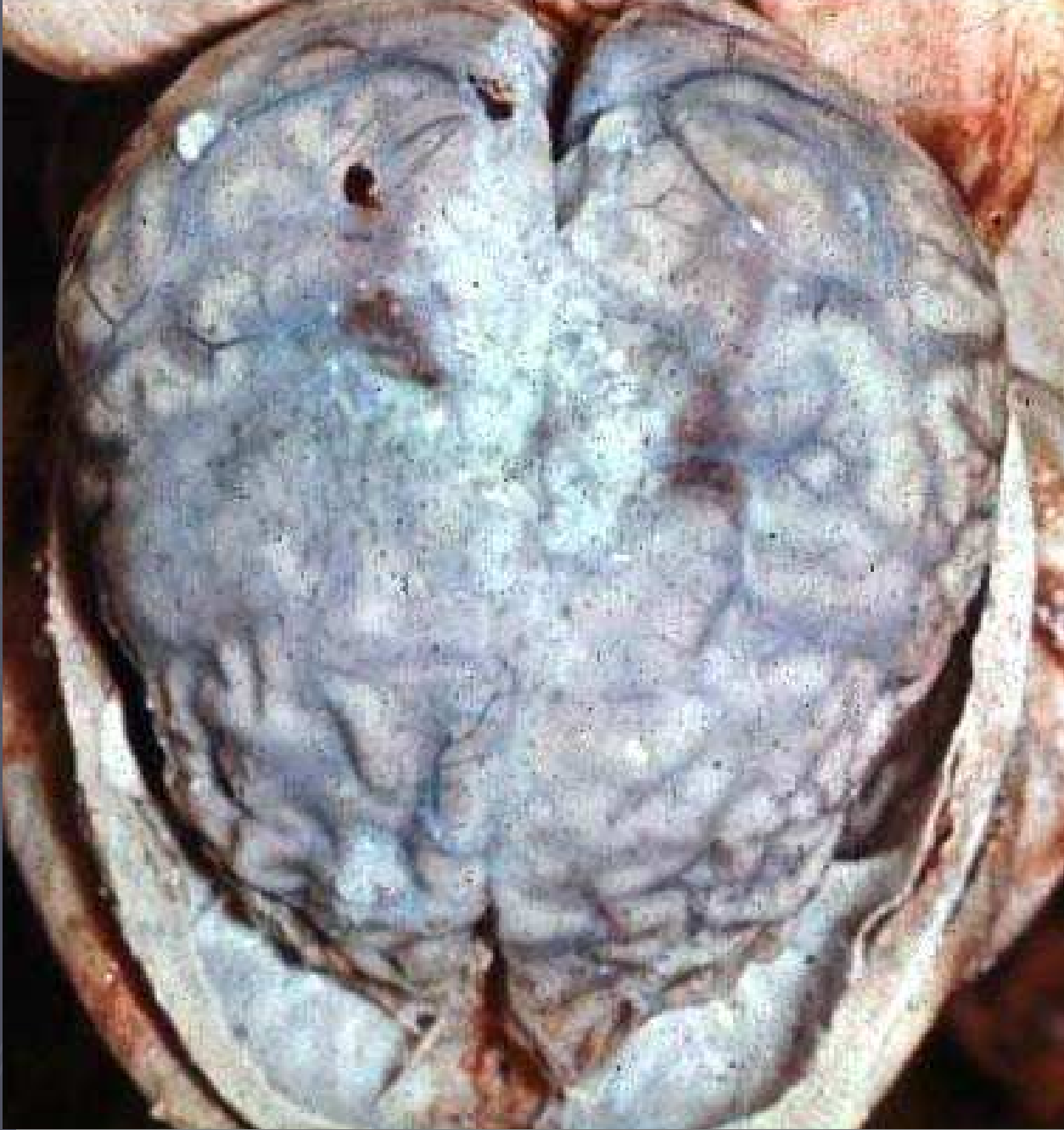
30 mm

Acut gyulladás típusai az exsudatum alapján:

- Serosus – inflammatio serosa
- Fibrinosus – inflammatio fibrinosa
- Purulens – inflammatio purulenta
- Vérzéses – inflammatio haemorrhagica
- Gangrenozus – inflammatio ichorosa seu gangraenosa

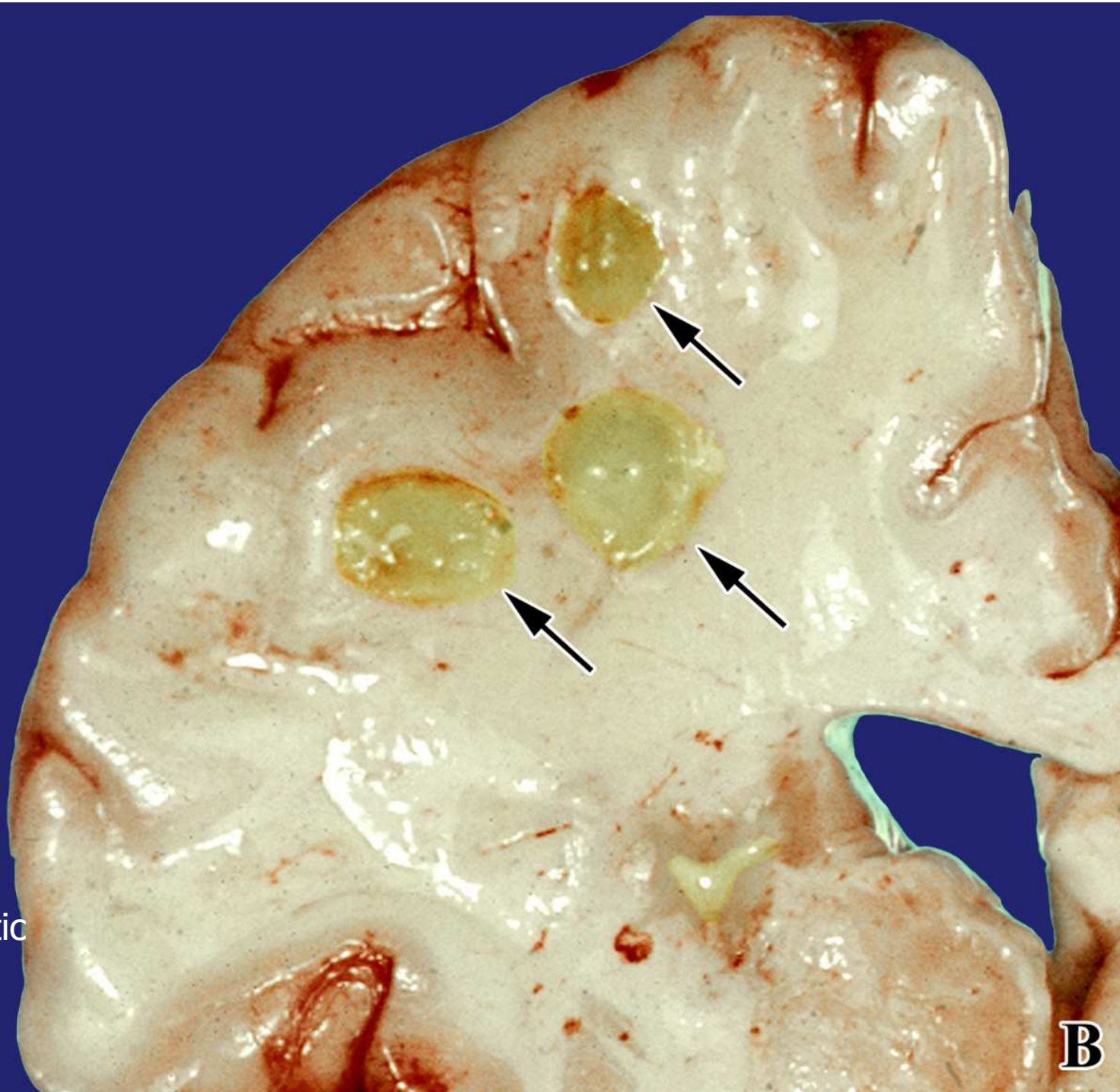
Pleuritis purulenta



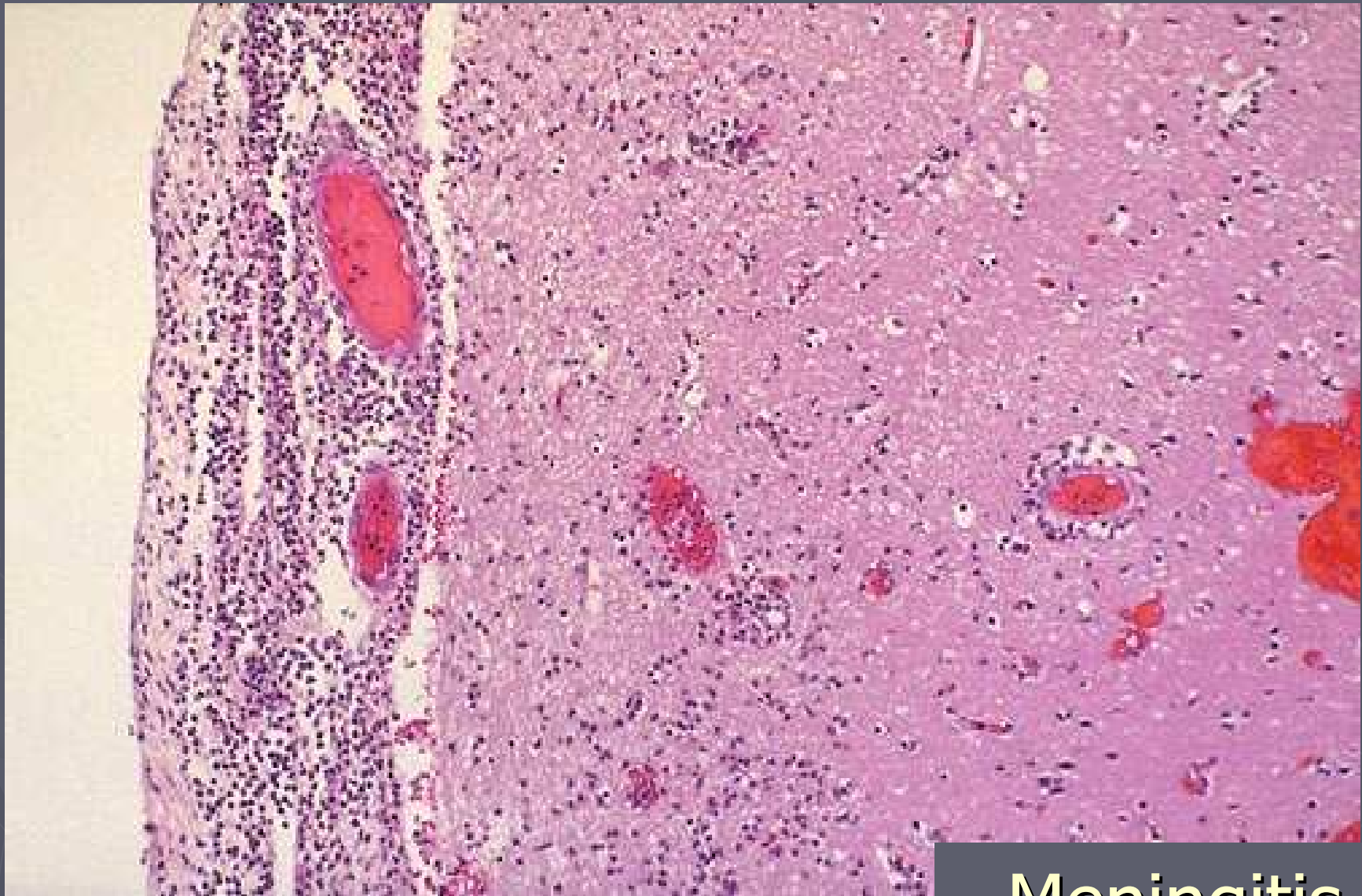


**Meningitis
purulenta**

Metastatic
brain
abscess

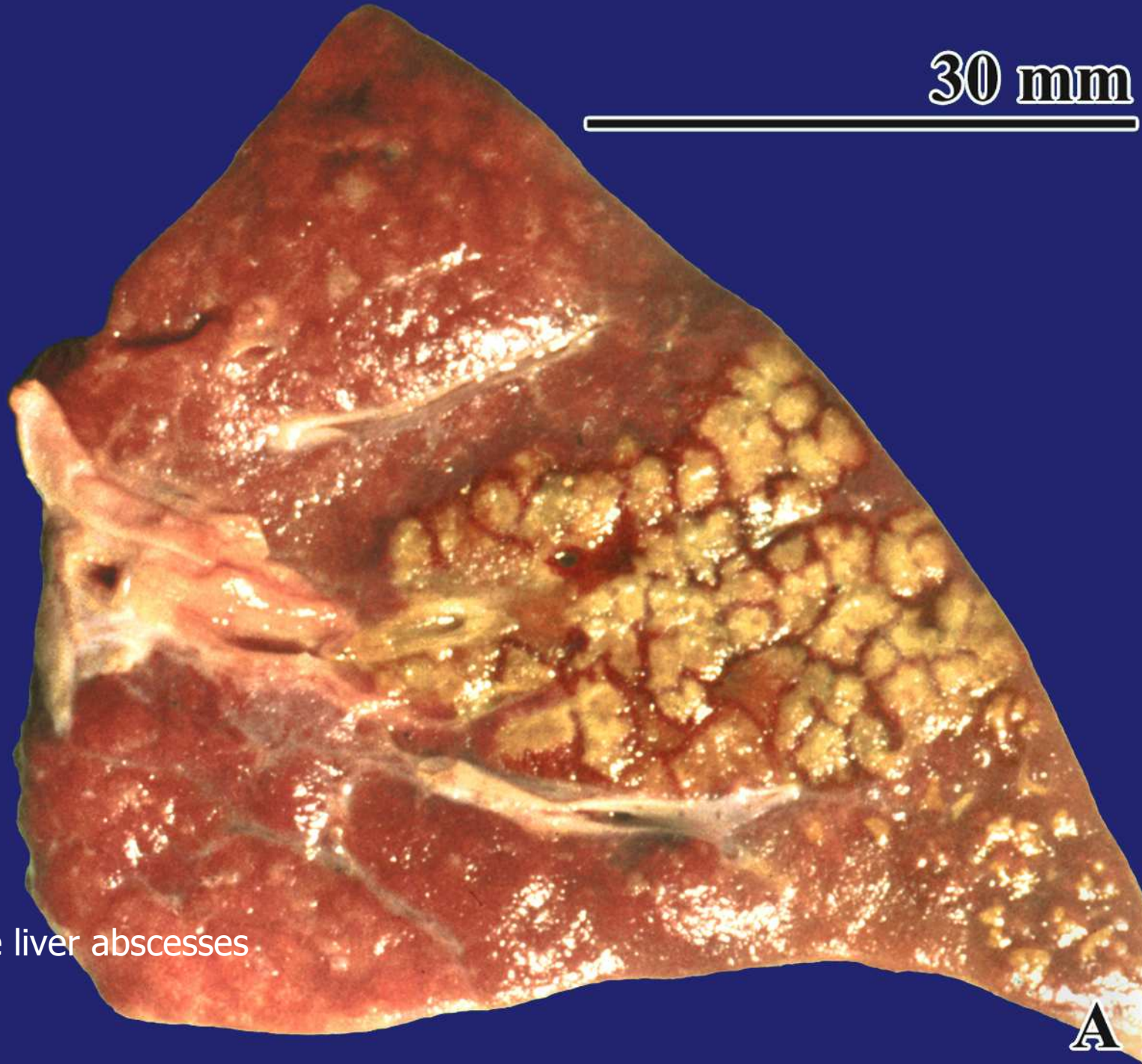


B



**Meningitis
purulenta**

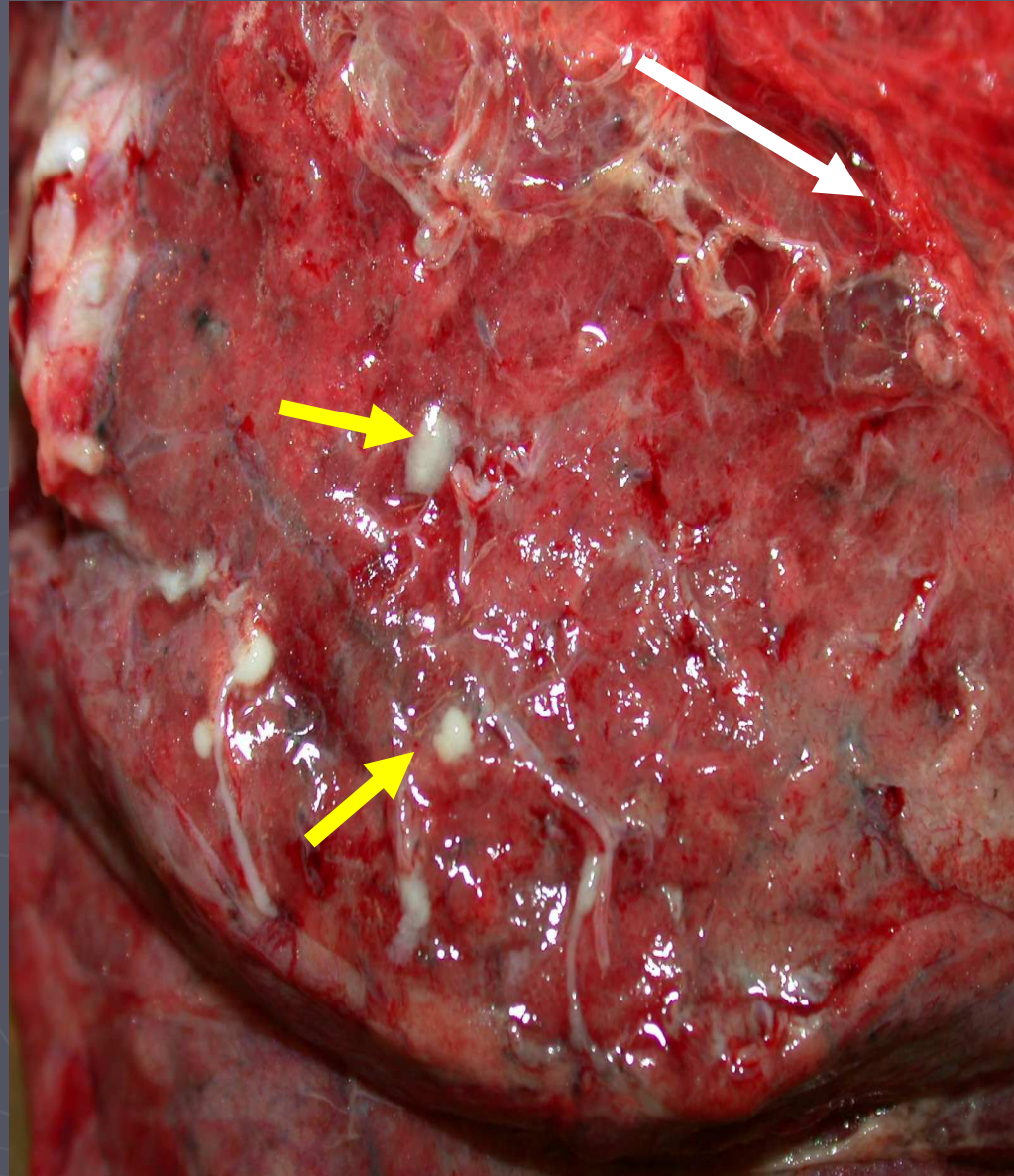
30 mm



Multiple liver abscesses

A

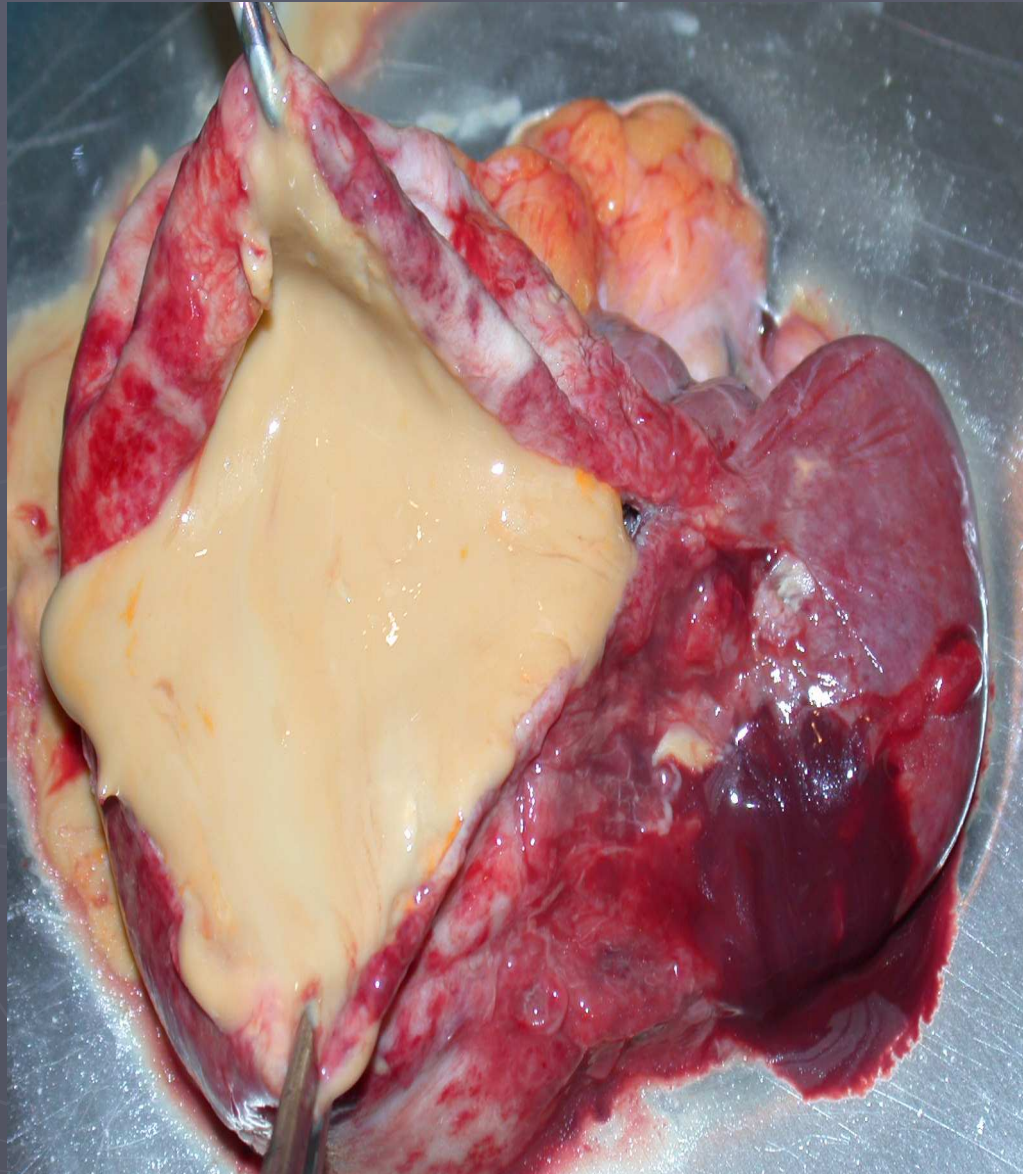Purulent bronchopneumonia



44761.04.24.

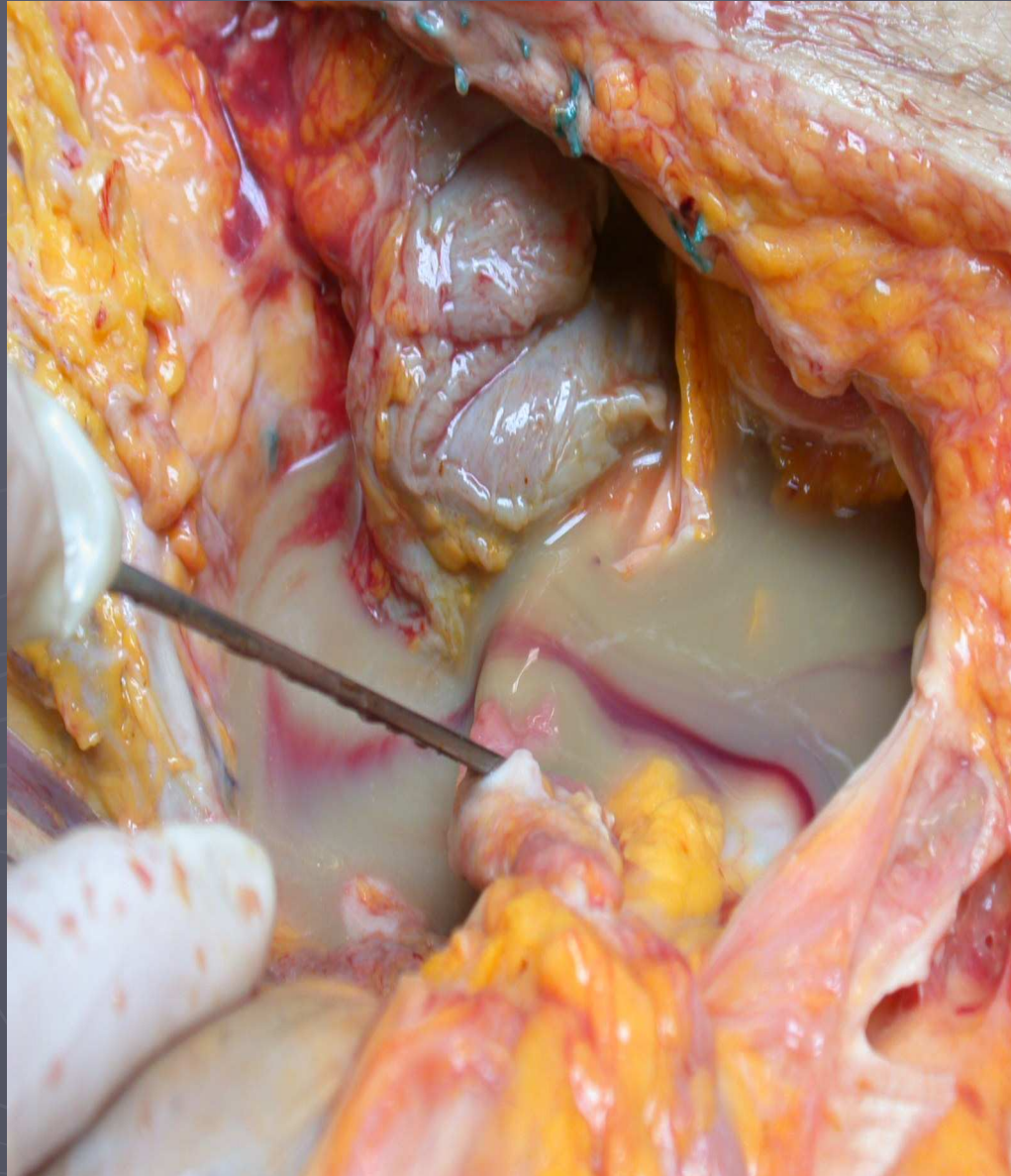
**Preformált üregek purulens
gyulladás, abscessus**

PUS



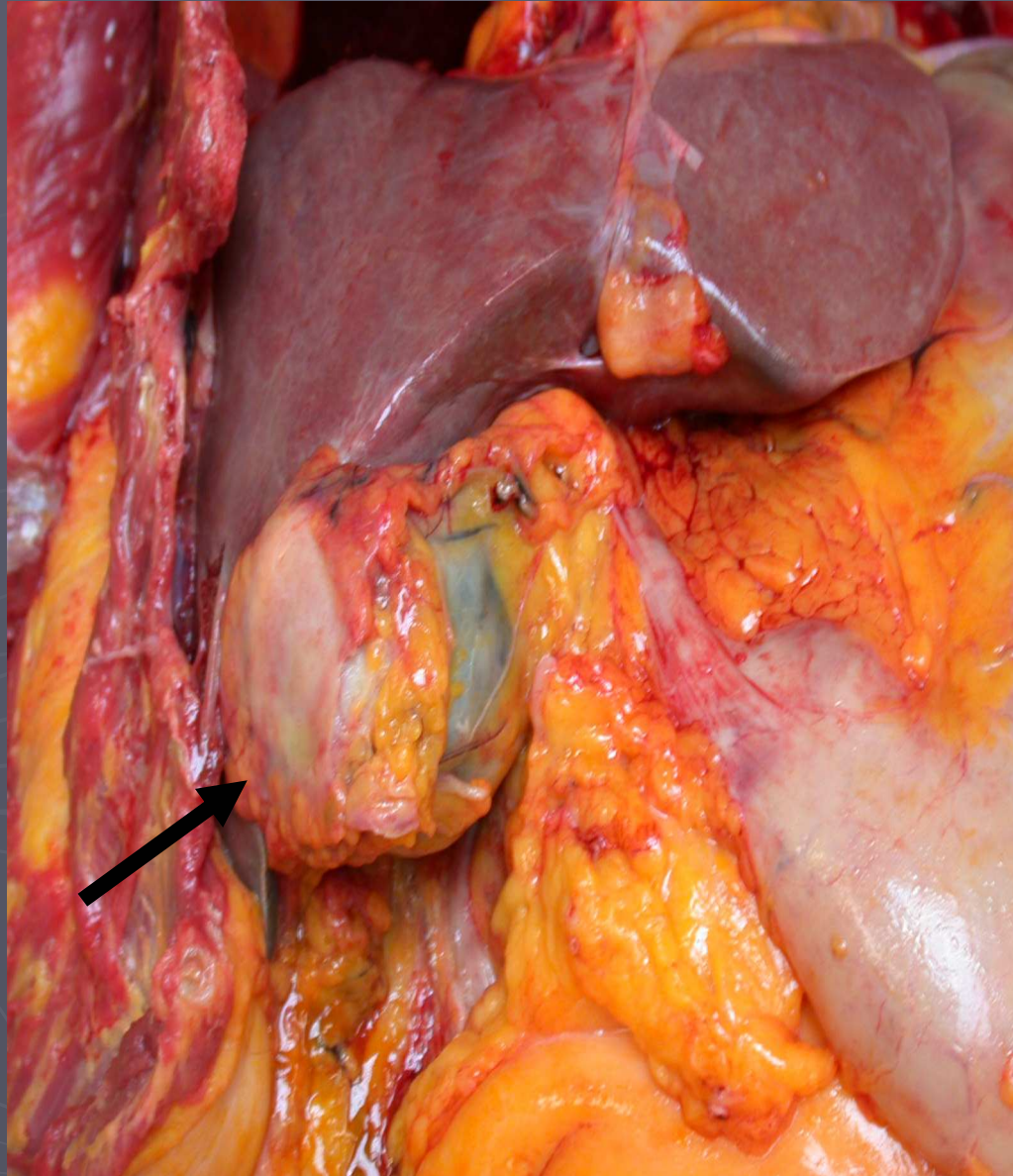
44756.04.05.

abscess



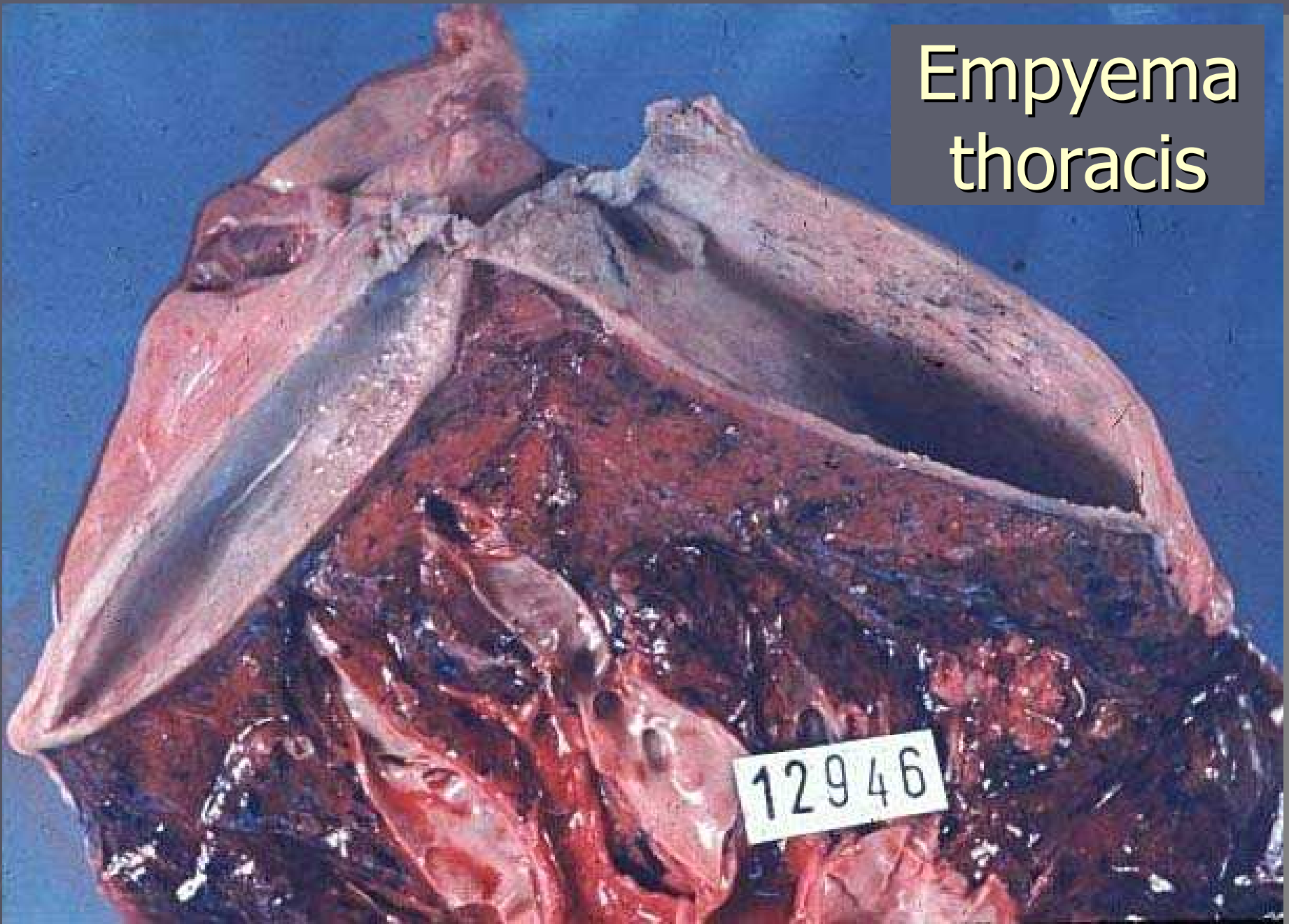
44704.04.28.

Empyema vesicae felleae

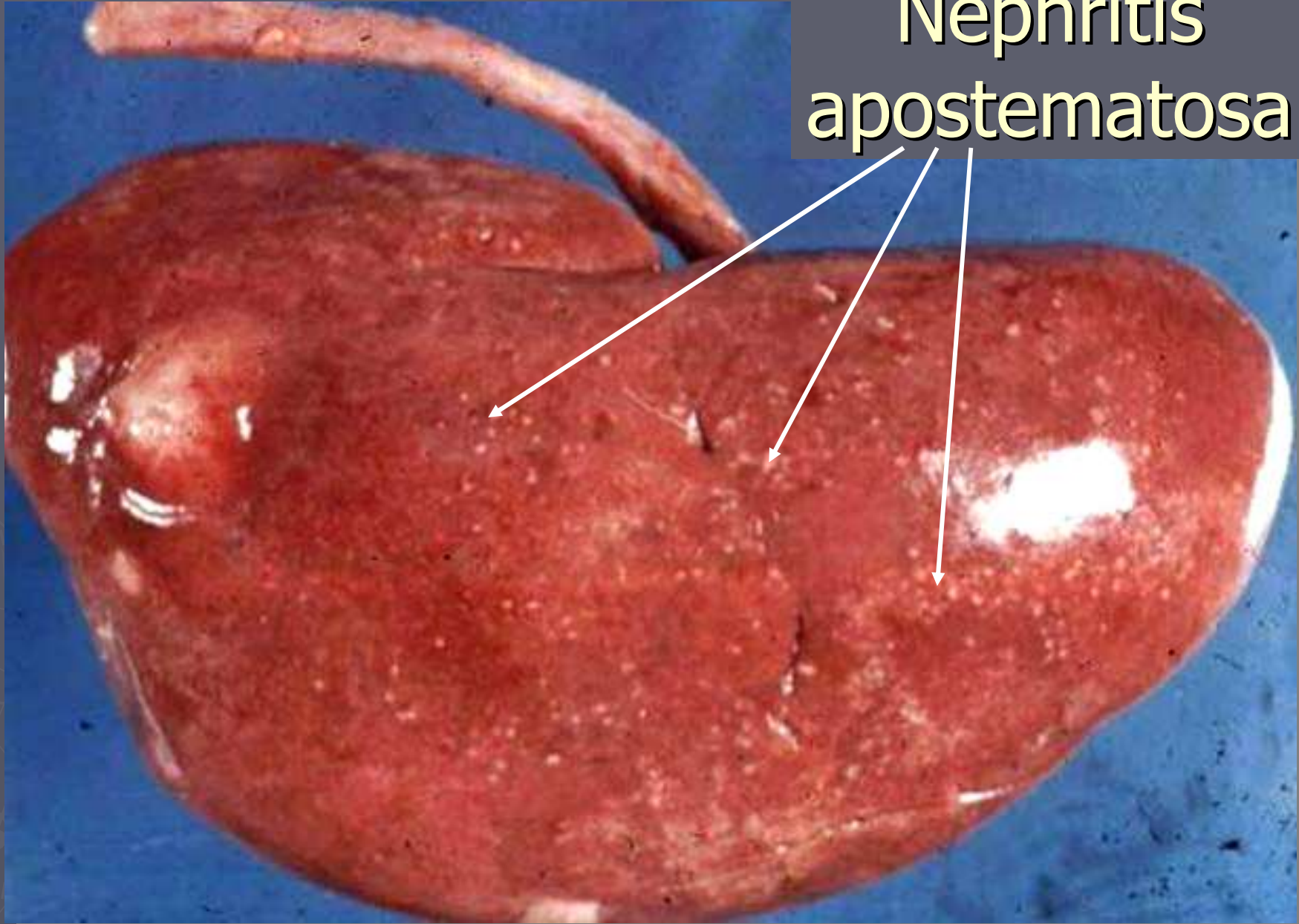


44754.04.18.

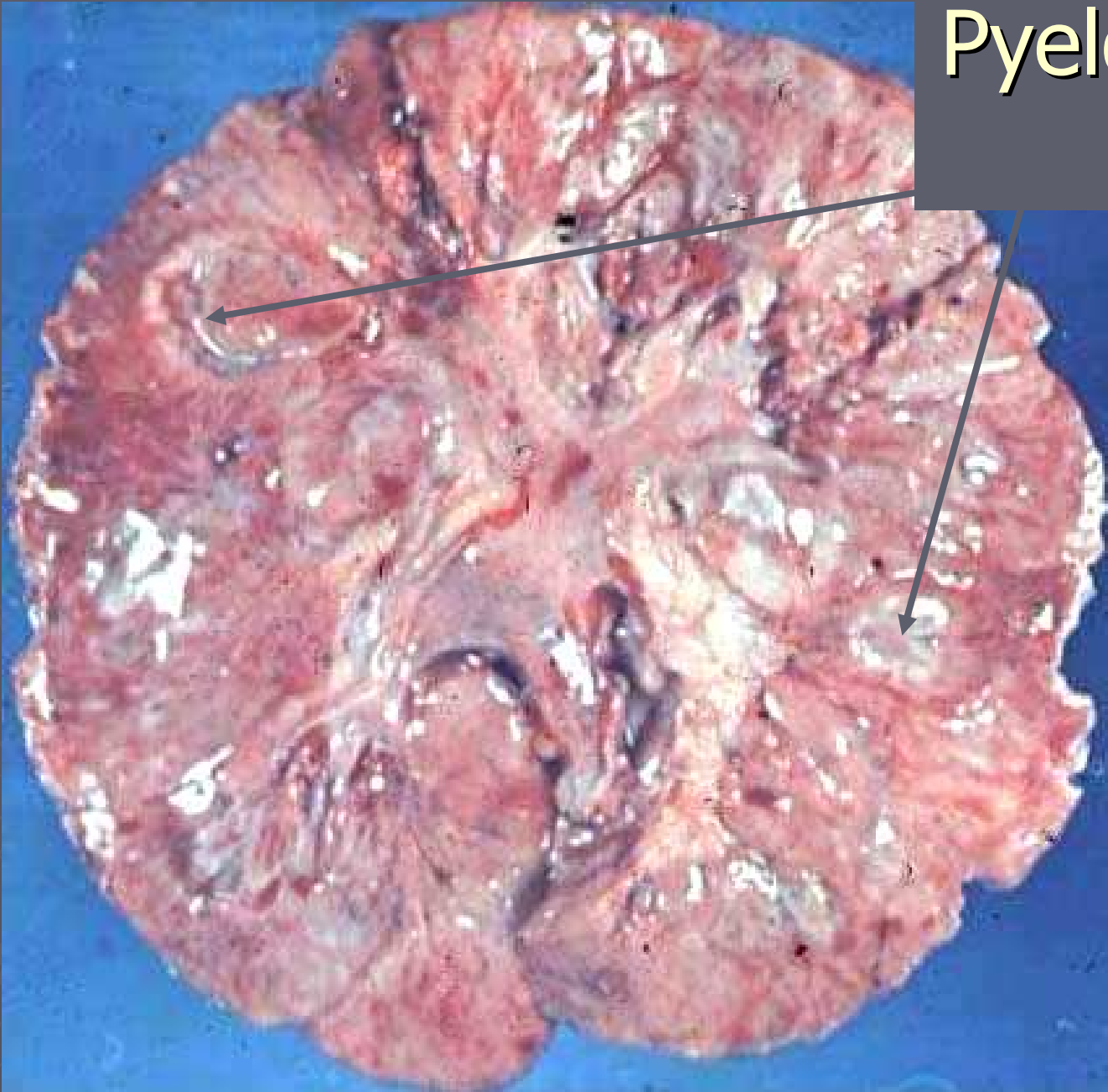
Empyema thoracis



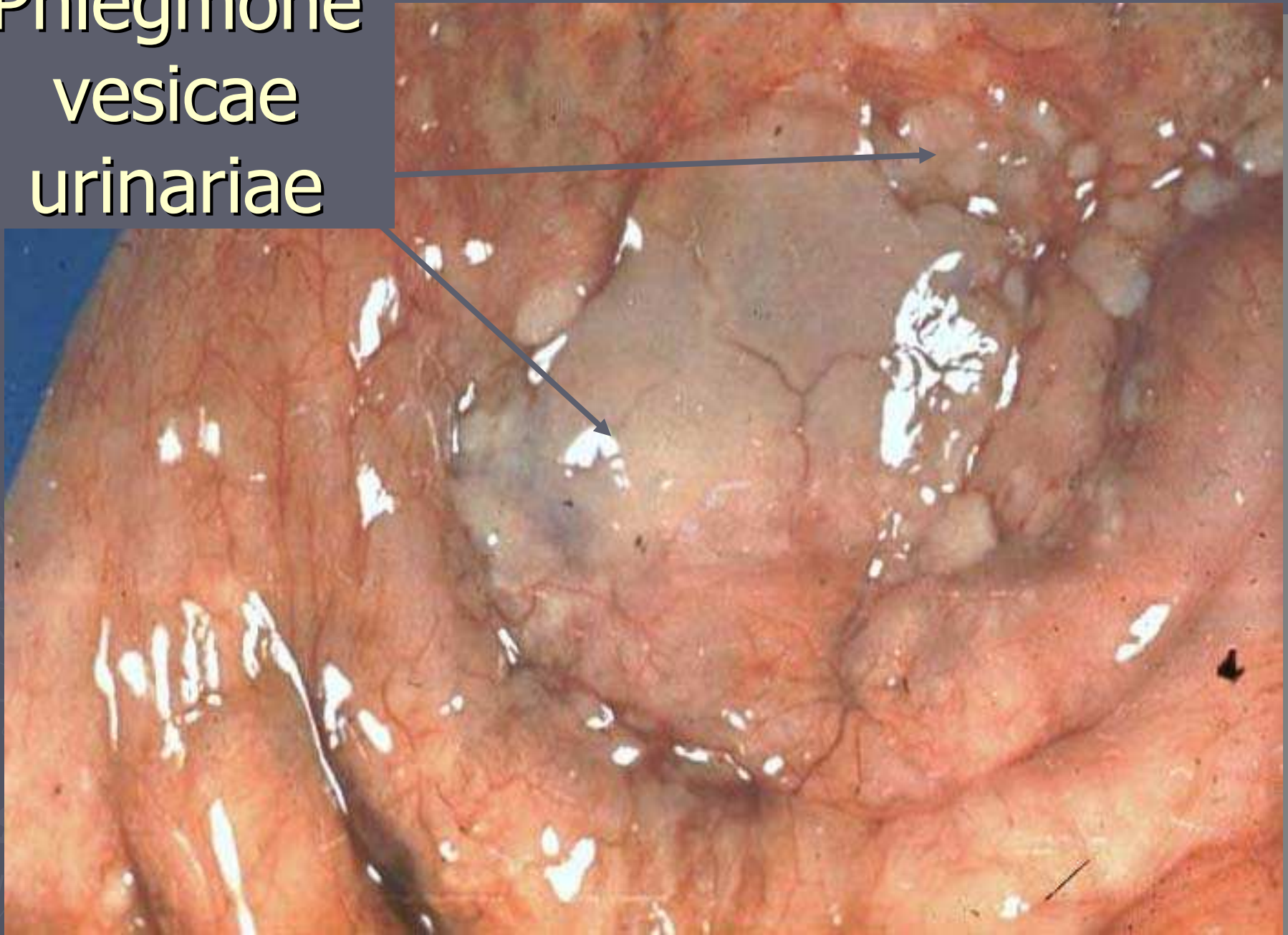
Nephritis apostematosa



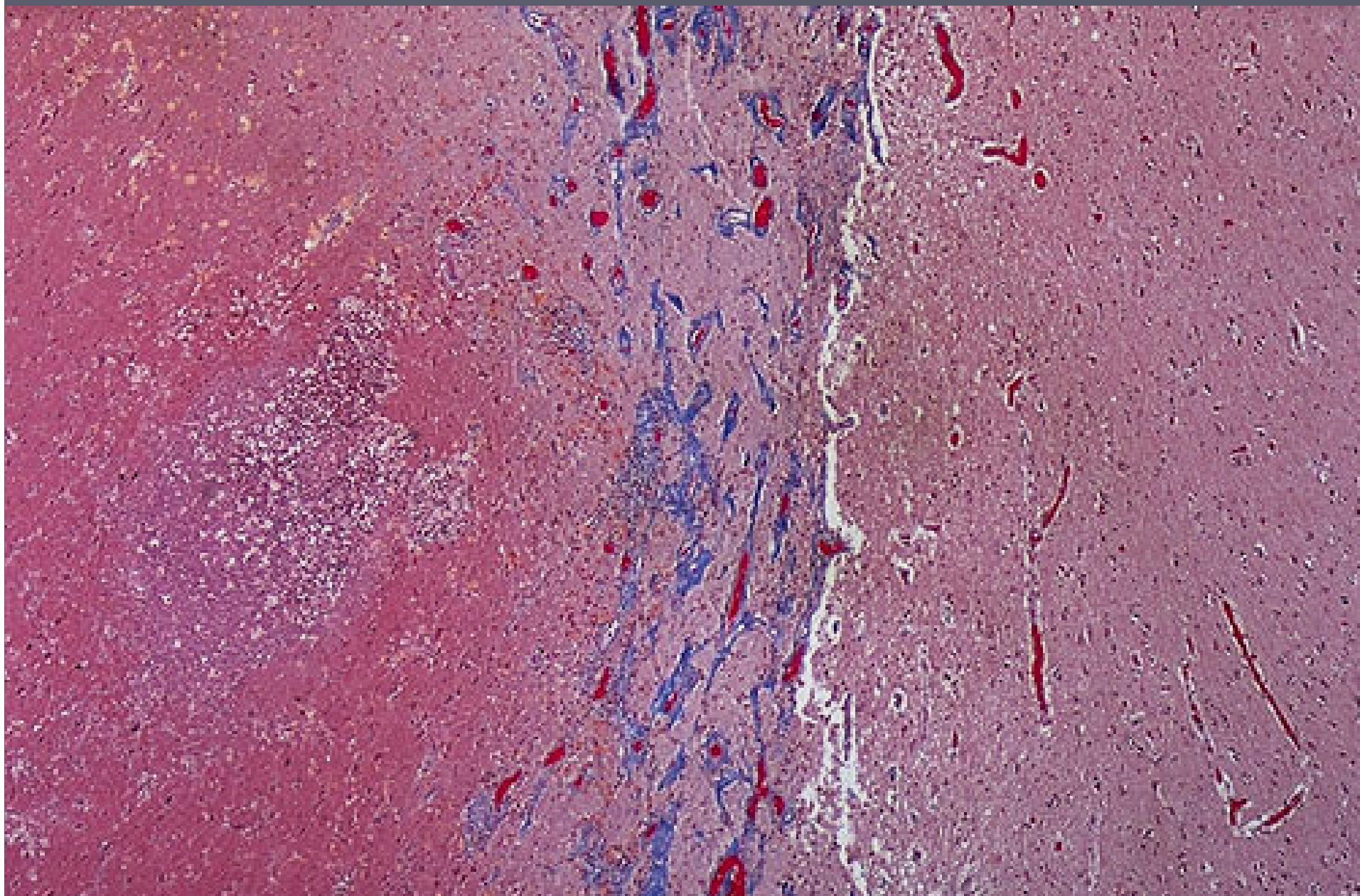
Pyelonephritis acuta

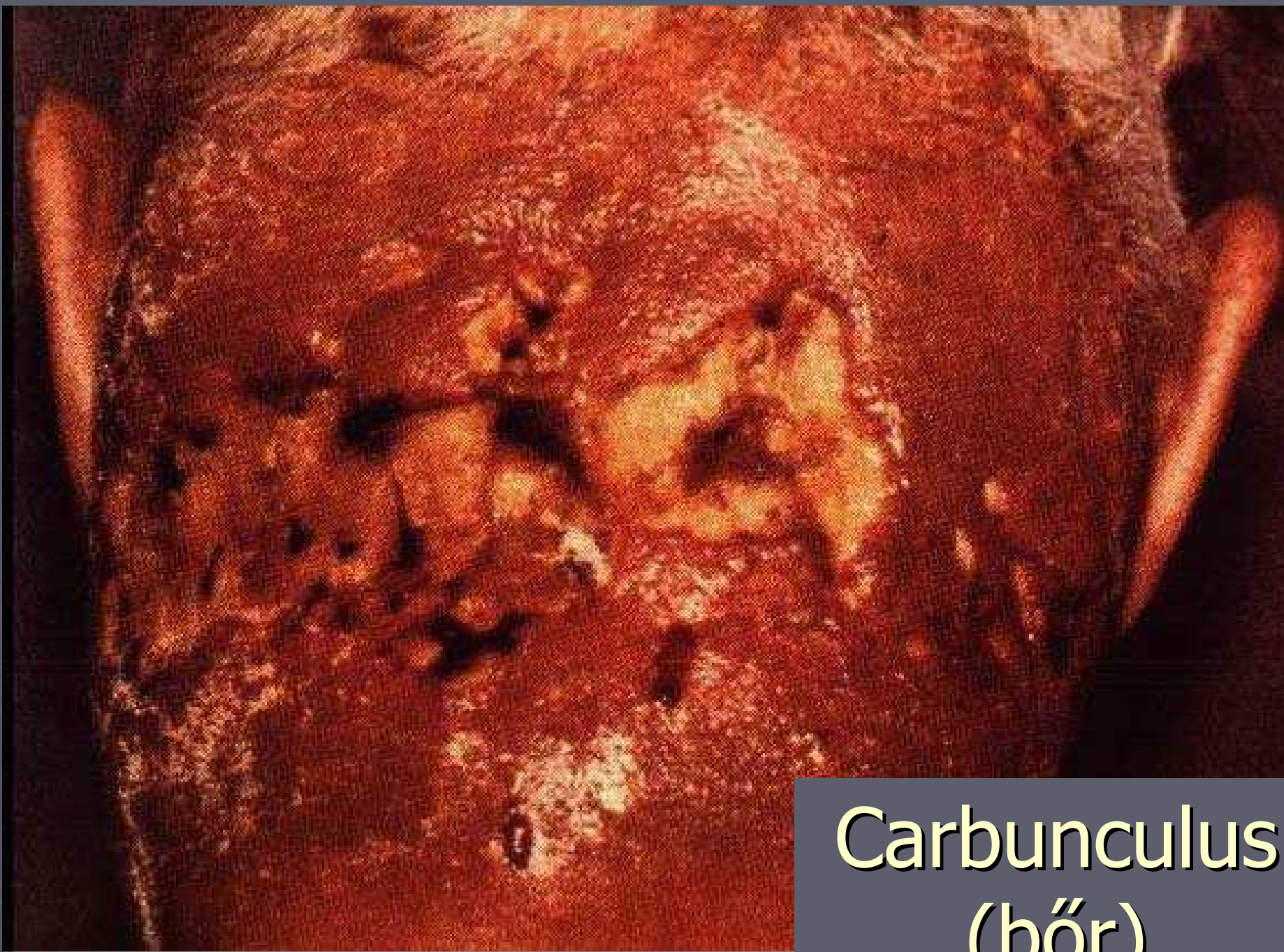

Phlegmone vesicae urinariae



Agyi tályog

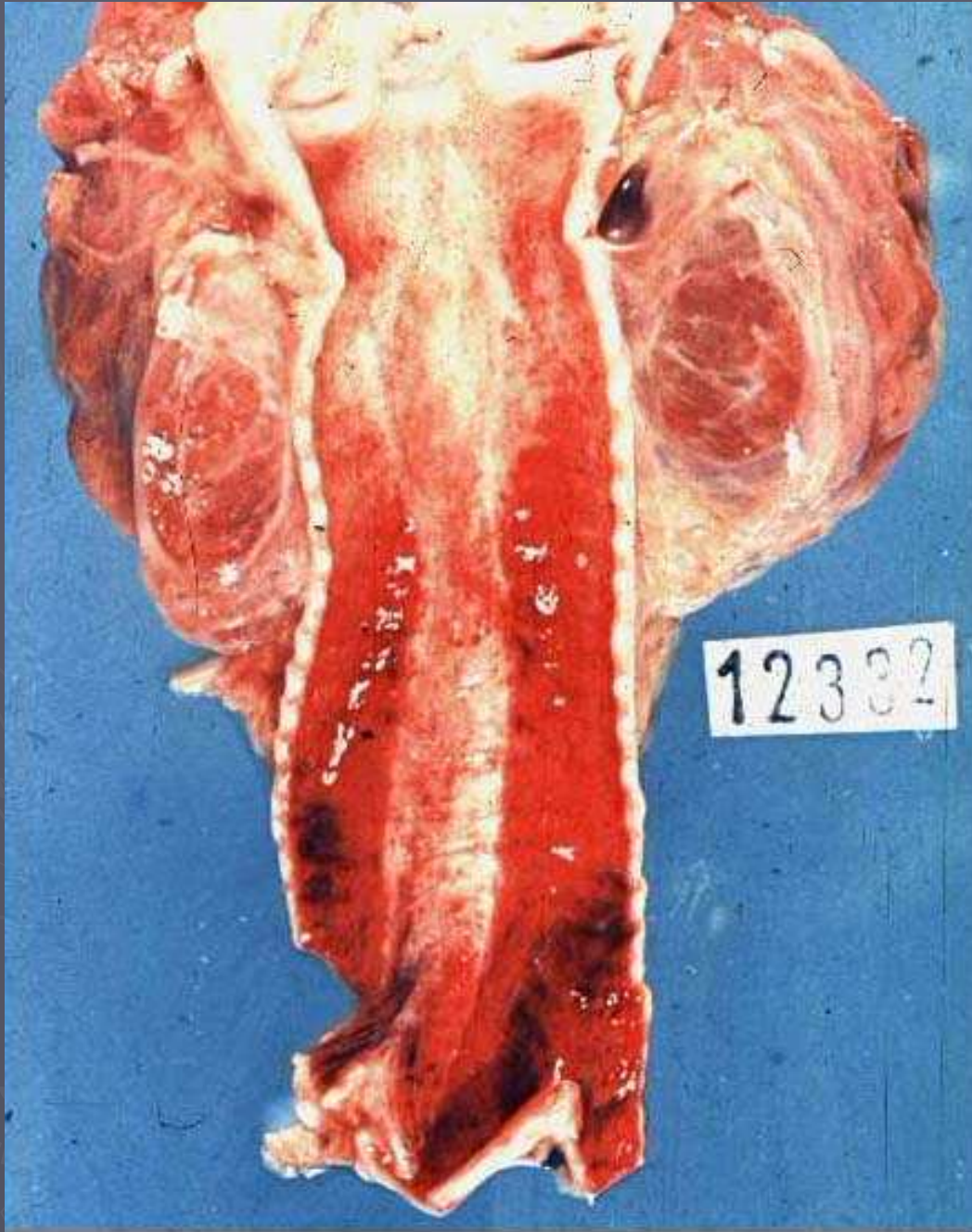




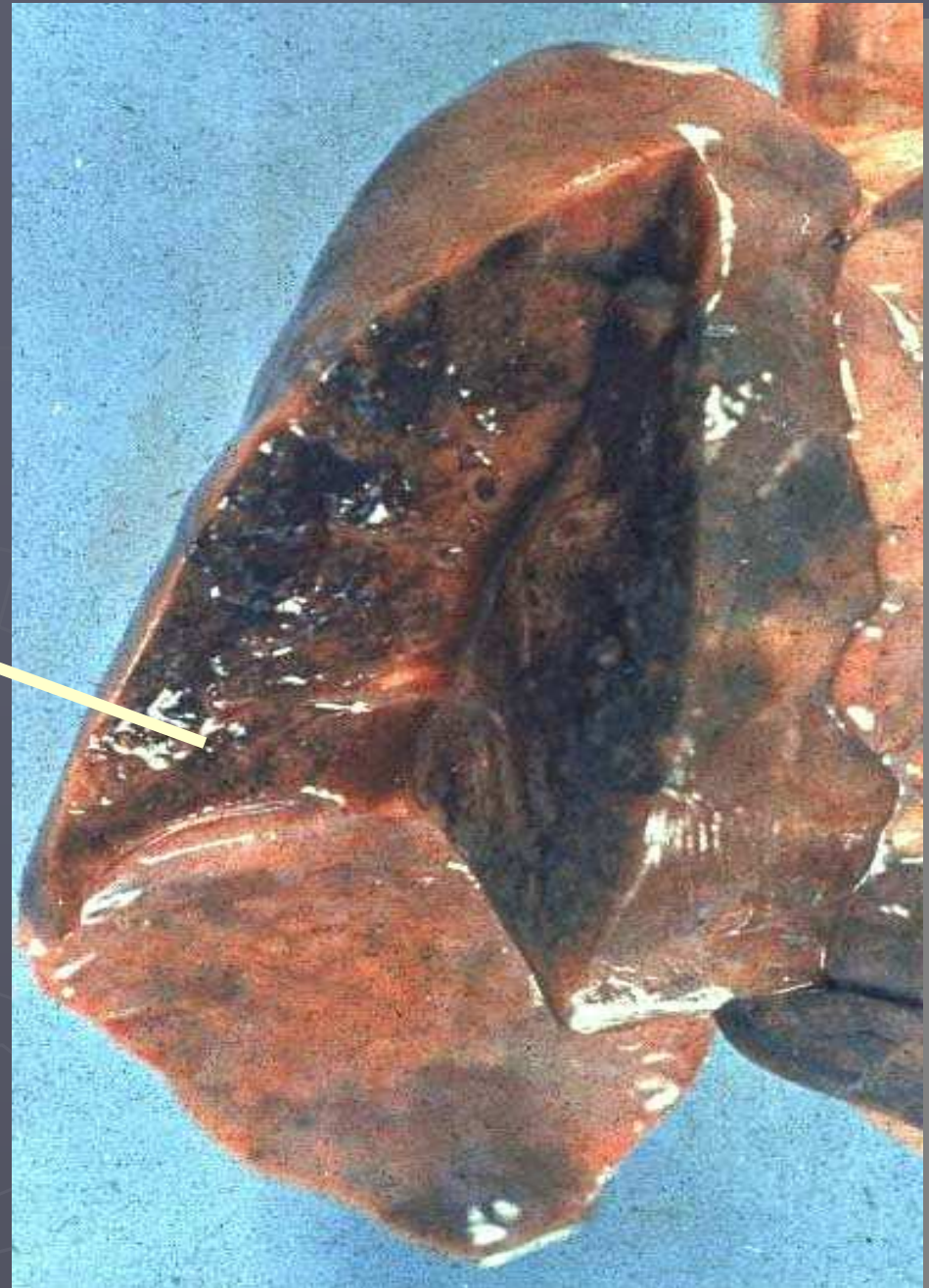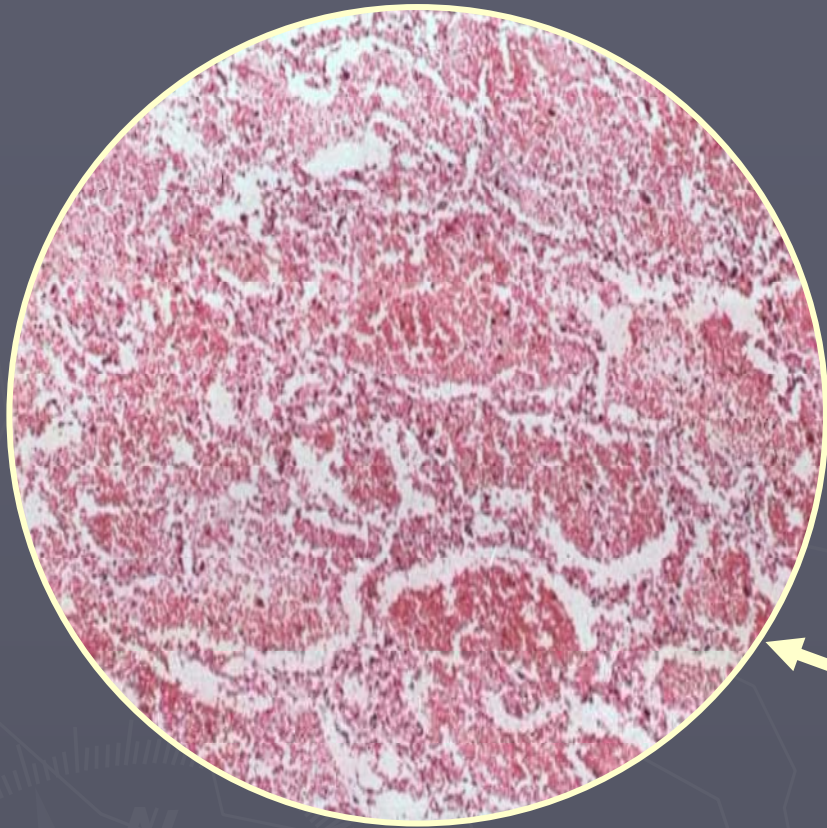
Carbunculus
(bőr)

Acut gyulladás típusai az exsudatum alapján:

- Serosus – inflammatio serosa
- Fibrinosus – inflammatio fibrinosa
- Purulens – inflammatio purulenta
- **Vérzéses – inflammatio haemorrhagica**
- Gangrenozus – inflammatio ichorosa seu gangraenosa



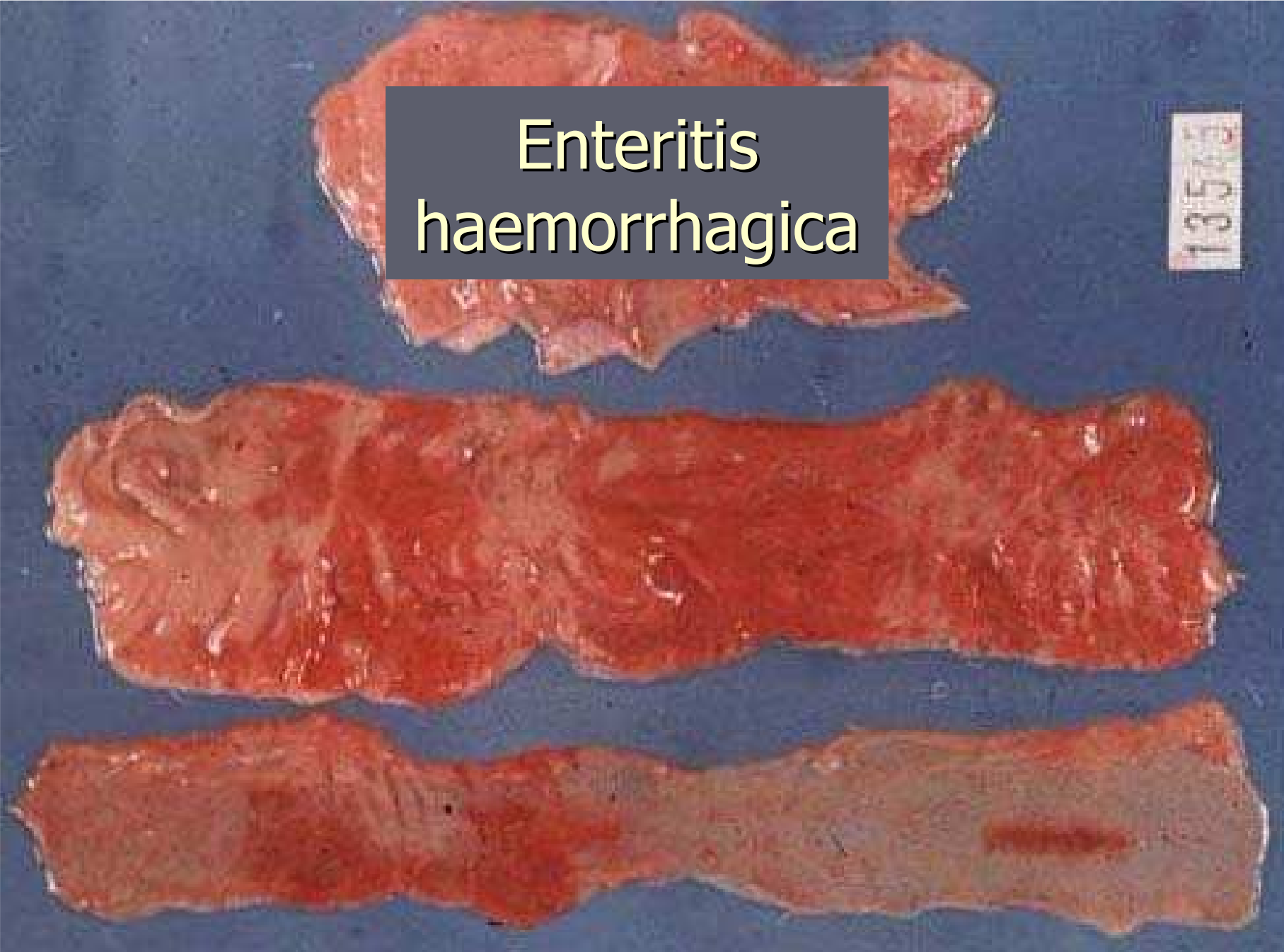Tracheitis
acuta
haemorrhagica



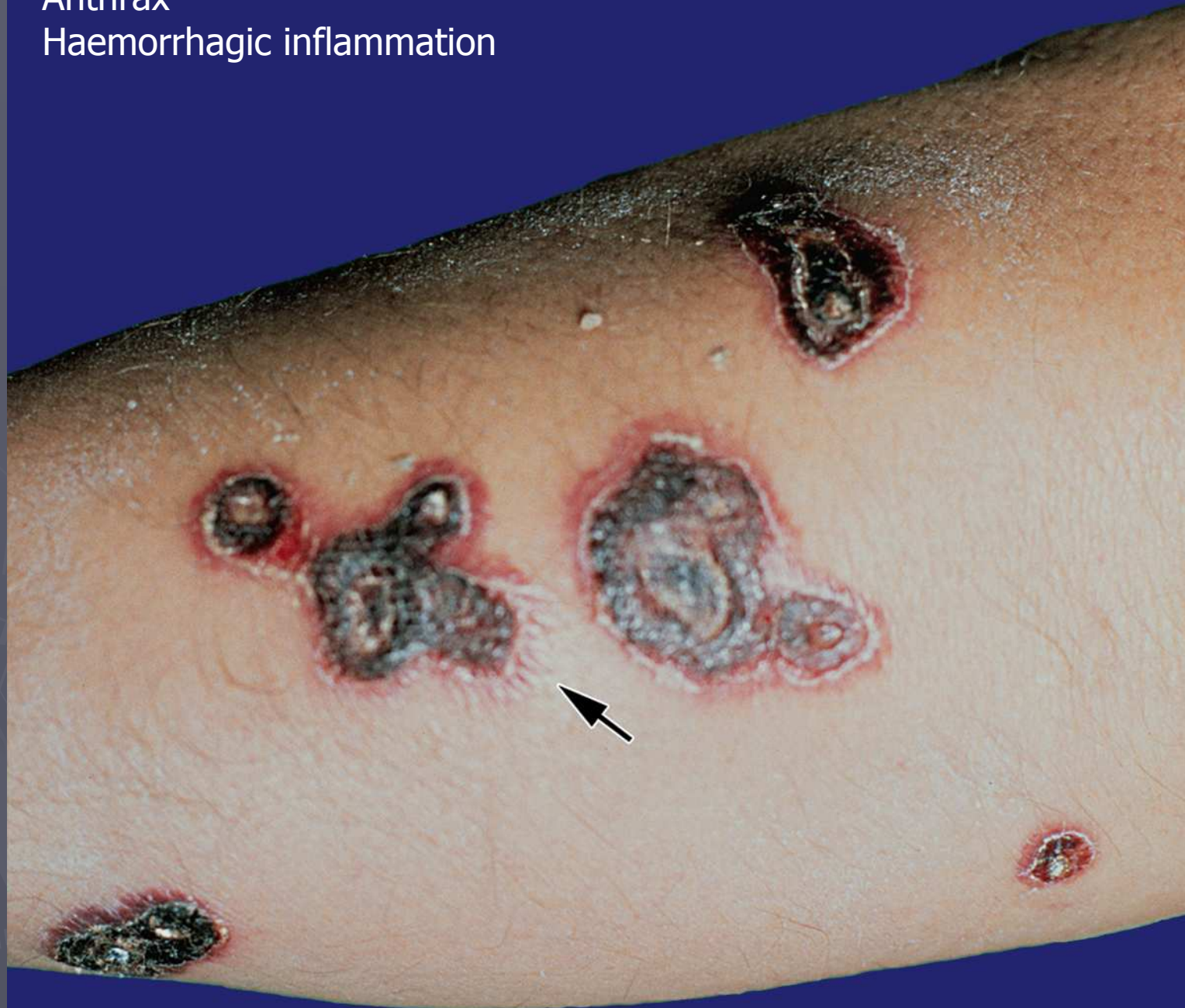Pneumonia
haemorrhagica

Enteritis haemorrhagica

1356a

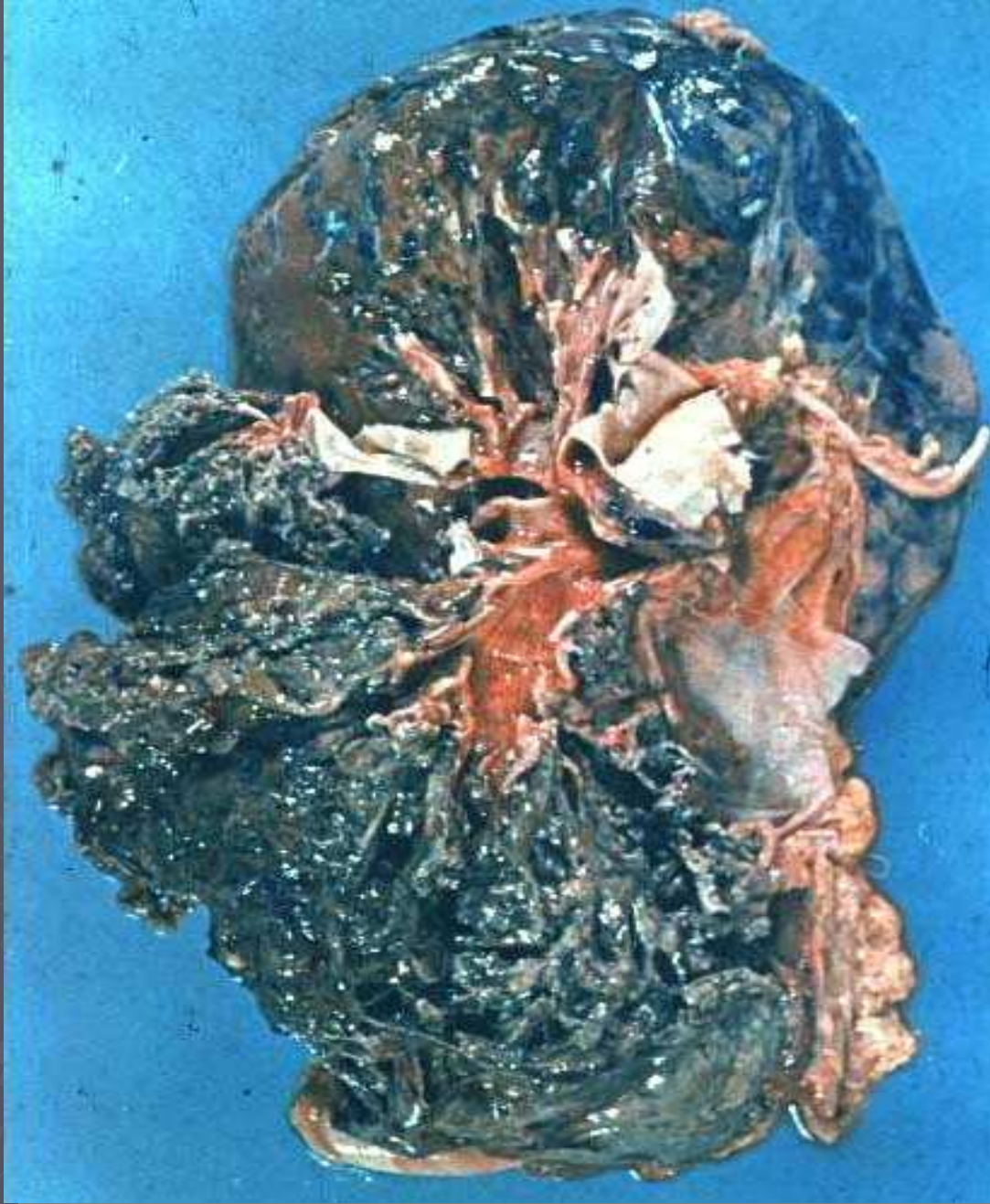

Anthrax
Haemorrhagic inflammation



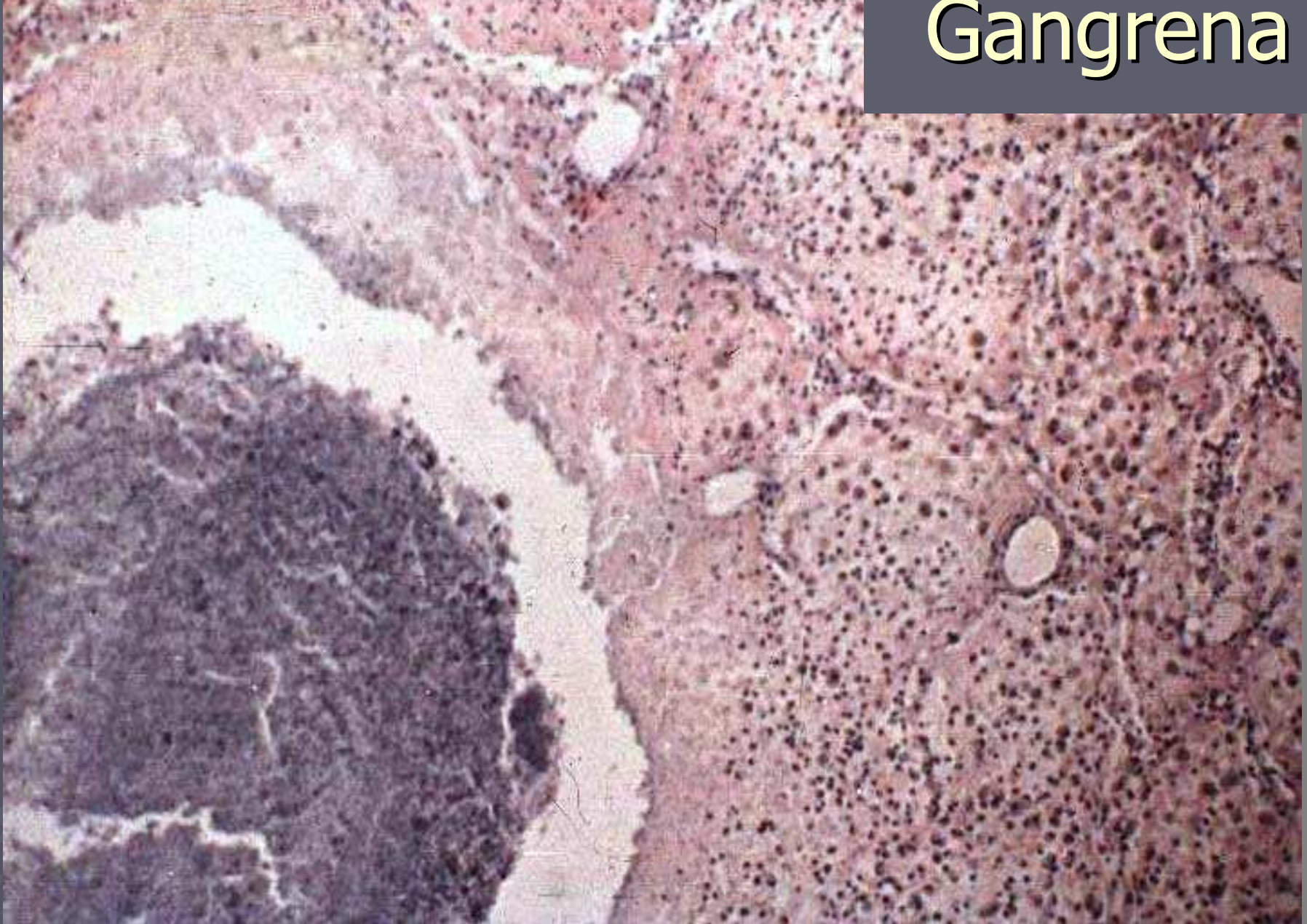Acut gyulladás típusai az exsudatum alapján:

- Serosus – inflammatio serosa
- Fibrinosus – inflammatio fibrinosa
- Purulens – inflammatio purulenta
- Vérzéses – inflammatio haemorrhagica
- Gangrenozus – inflammatio ichorosa seu gangraenosa



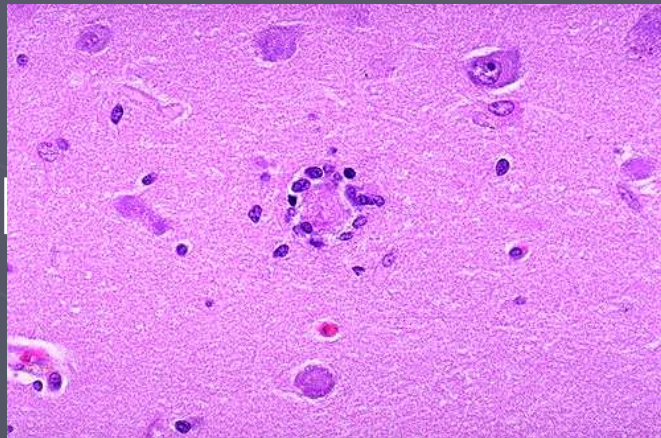
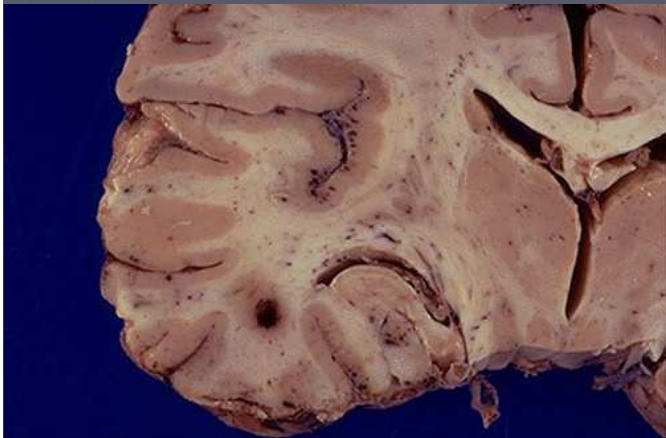Gangrena
pulmonum

Gangrena

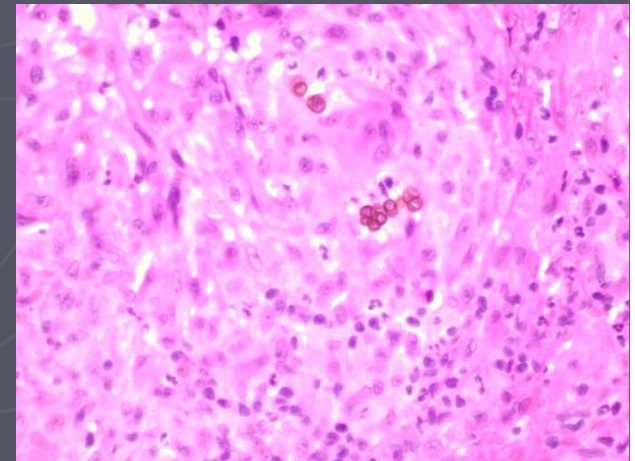



Acut gyulladás, exsudatum, kórokok

- ▶ Bacterialis: purulens, neutrofil predominancia
- ▶ Virusos: serozus/hemorragias, limfocita/makrofág



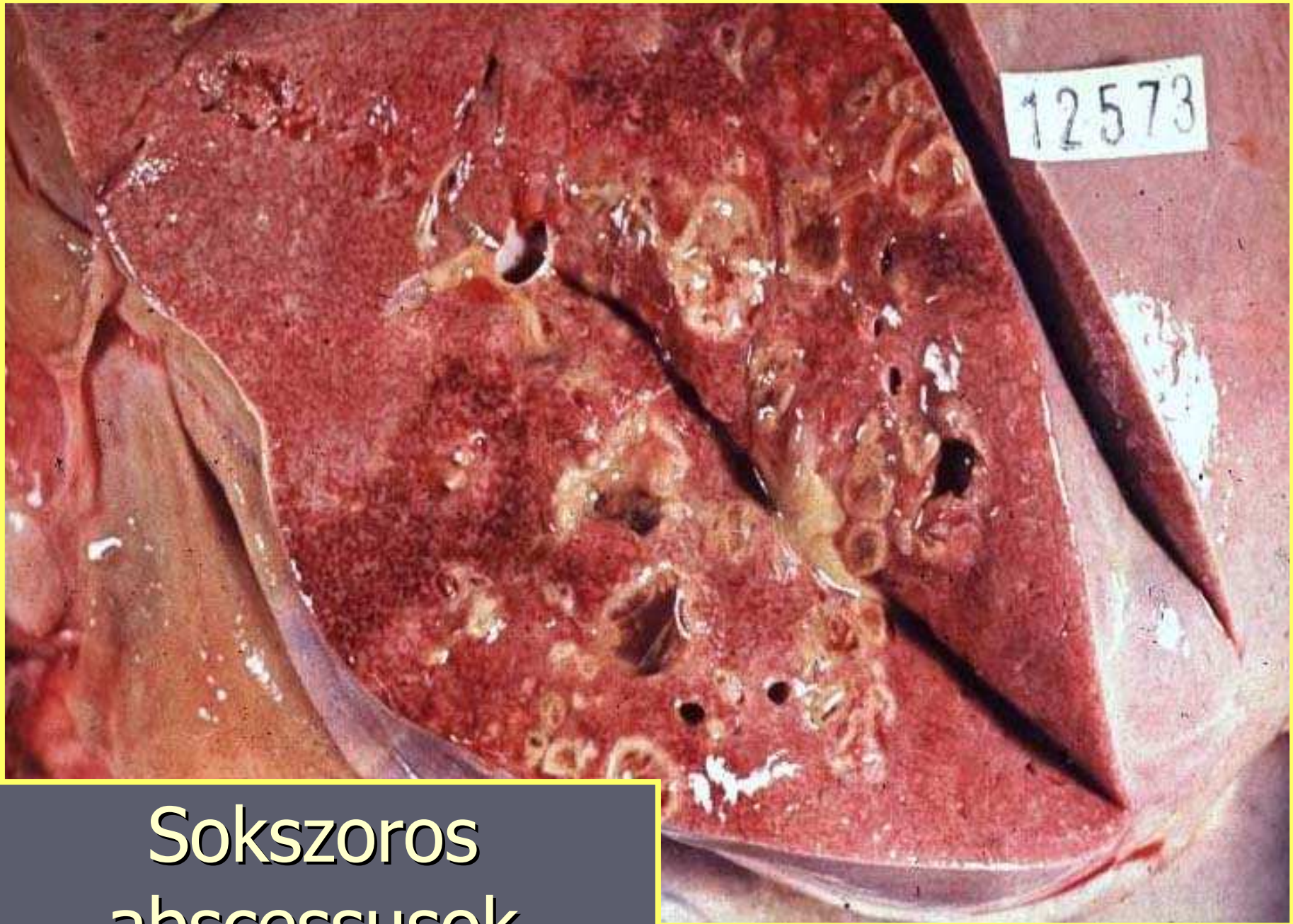
- ▶ Gombás, neutro+ eosinophyl



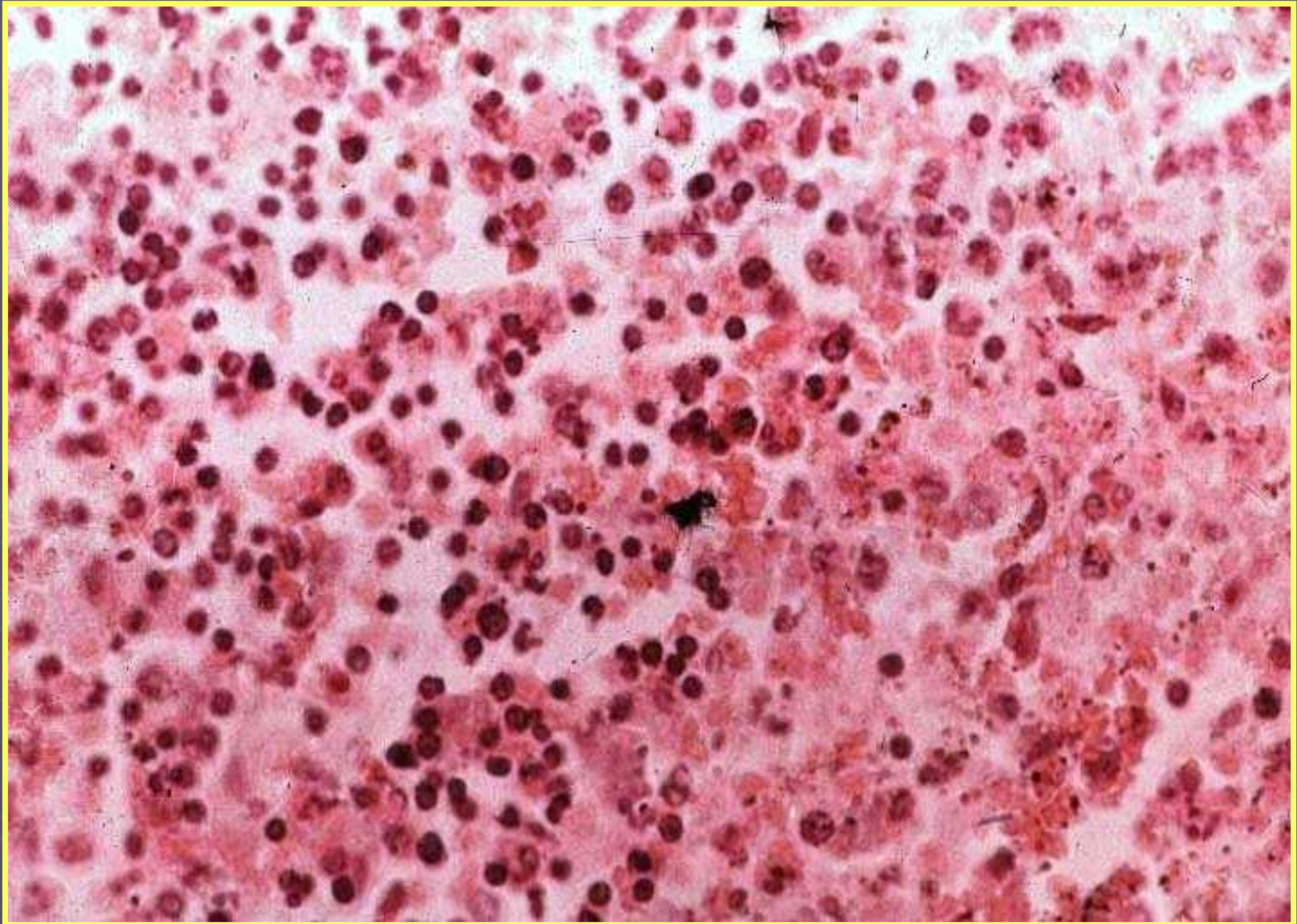


Sepsis

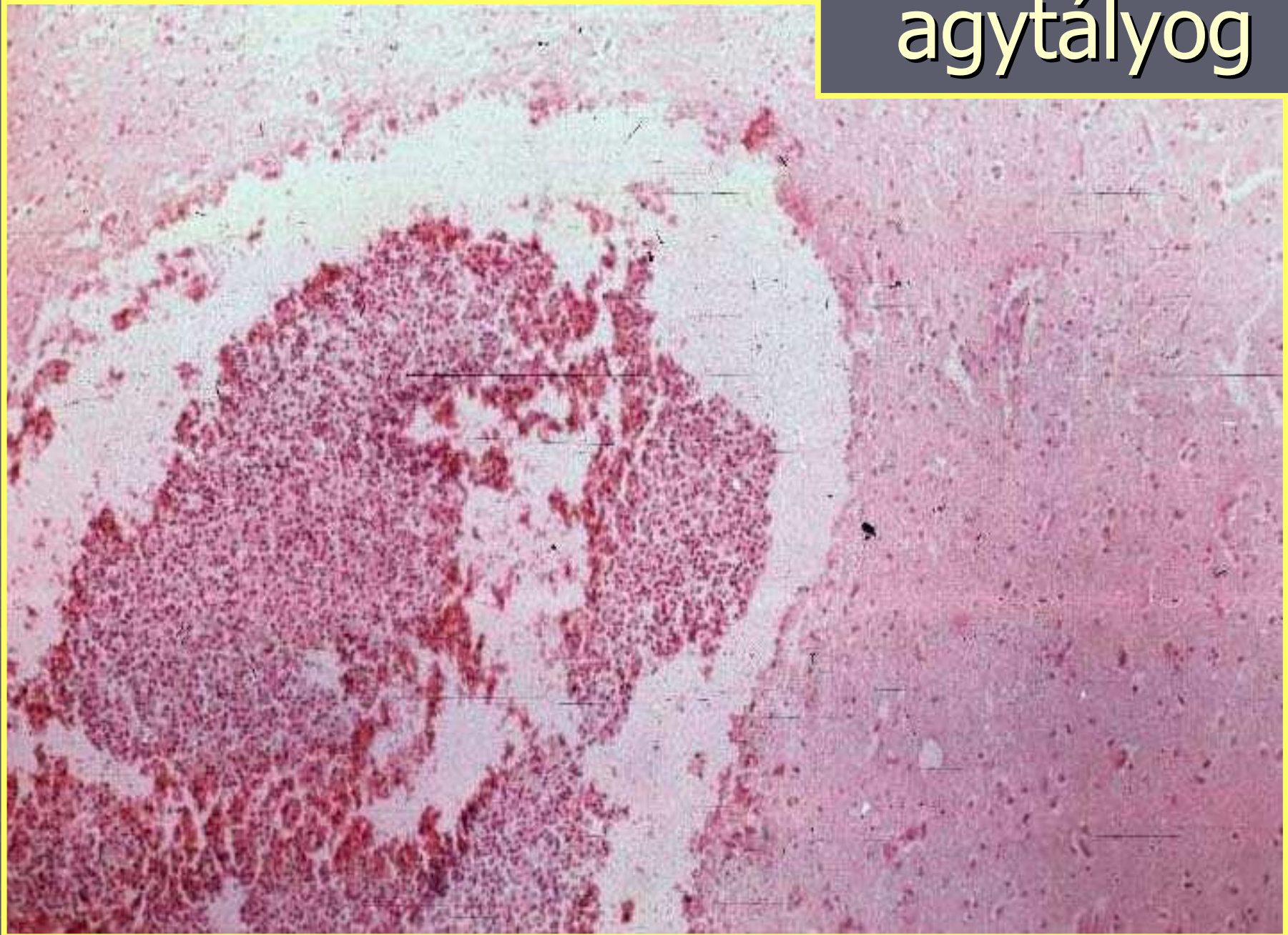keringő kórokozó+
szisztémás acut gyulladáso
tünetek
szeptikus shock.....

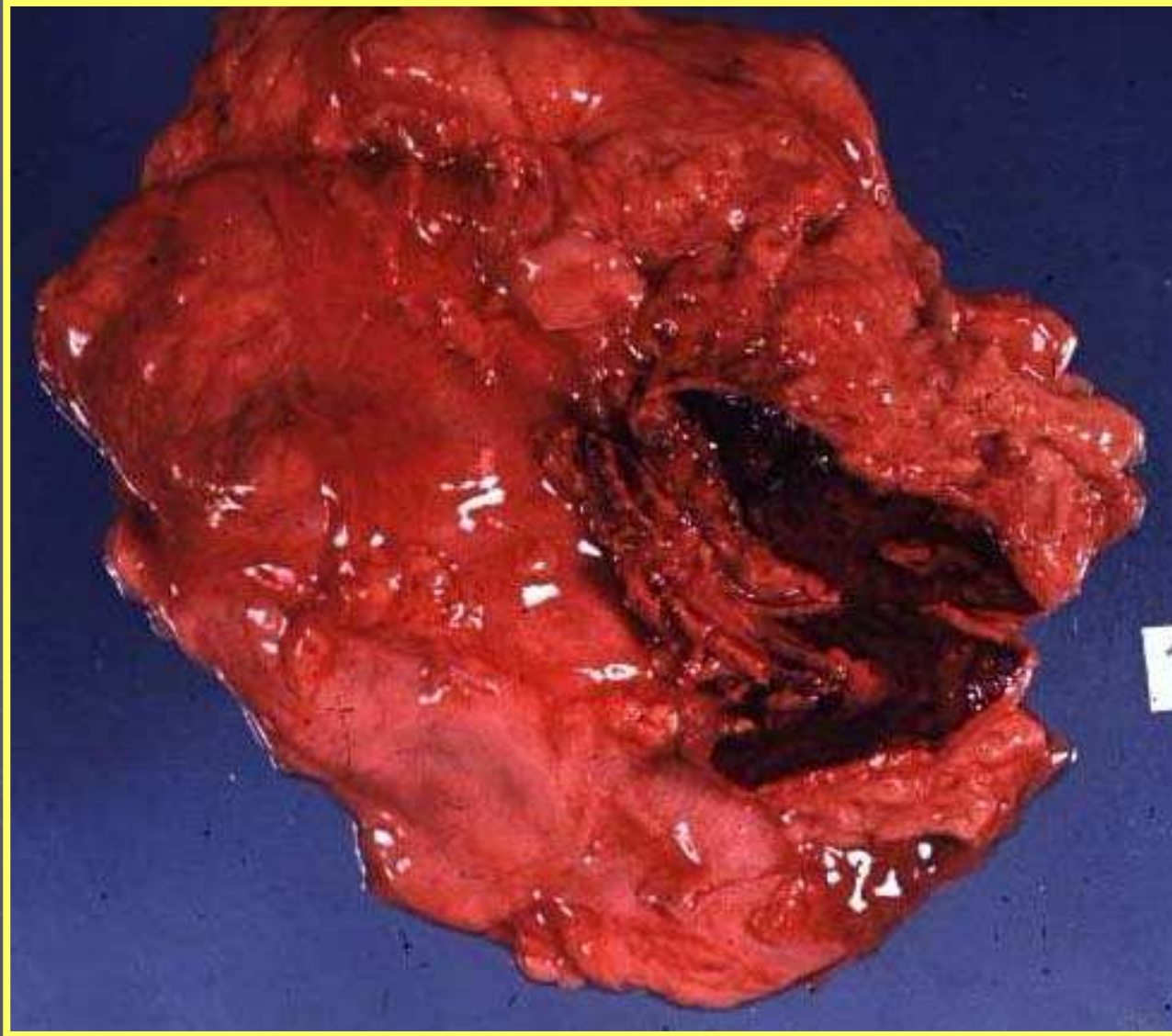


Sokszoros
abscessusok



agytályog





mellékvesevézés
meningococcus sepsis

Gyulladás formái

- ▶ **Acut**
- ▶ **Subacut**
- ▶ **Chronicus**



Subacut gyulladás

- ▶ Hetek, 1-2 hónap
- ▶ Csökkenő exsudatum
- ▶ Csökkenő oedema
- ▶ Eosinophil, lymphocyta
- ▶ **NOXIOUS AGENT + INFLAMMATION + REPARATION**

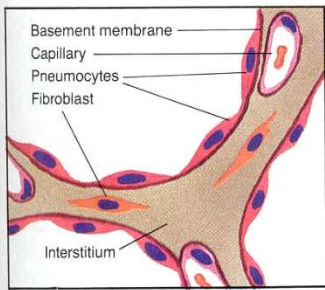
gyógyulás

REGENERáció:

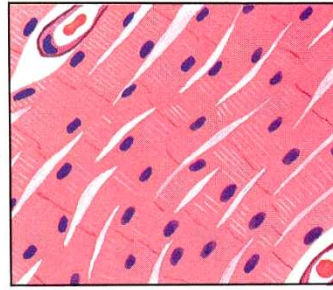
*az elpusztult szövet pótlása
identikus sejtekkel*

Hegesedés

*Az elpusztult szövet pótlása
kötőszövettel*



TISSUE OF LABILE OR STABLE CELLS
Normal lung



TISSUE OF PERMANENT CELLS
Normal heart

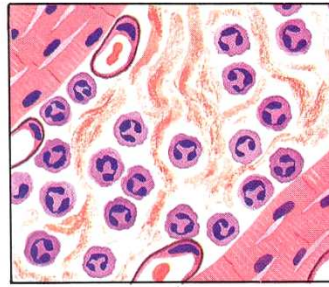
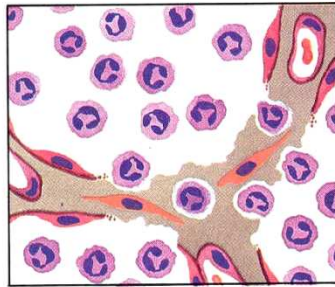
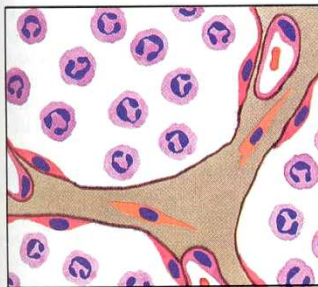
TISSUE INJURY

NECROSIS

Acute inflammation with
intact extracellular matrix

Damaged
extracellular matrix

Acute inflammation



Regeneration

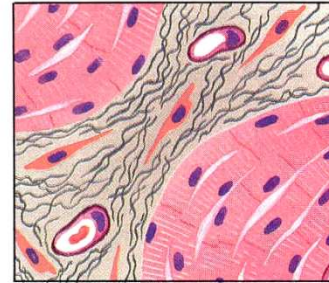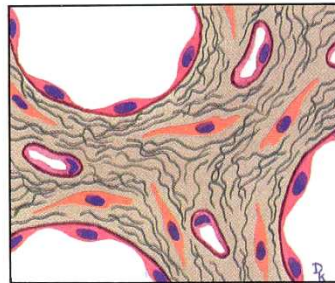
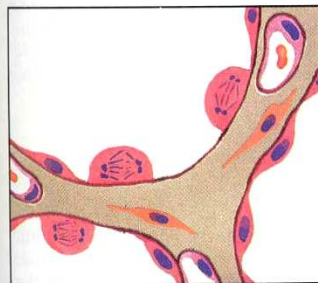
Fibrosis

Fibrosis

Normal lung

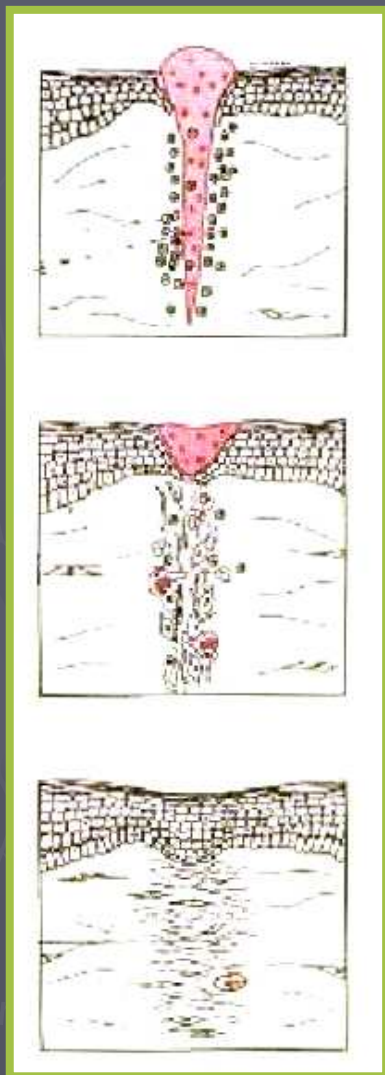
Interstitial fibrosis

Myocardial scar



Stabil és labil sejtek....

Primer sebgyógyulás

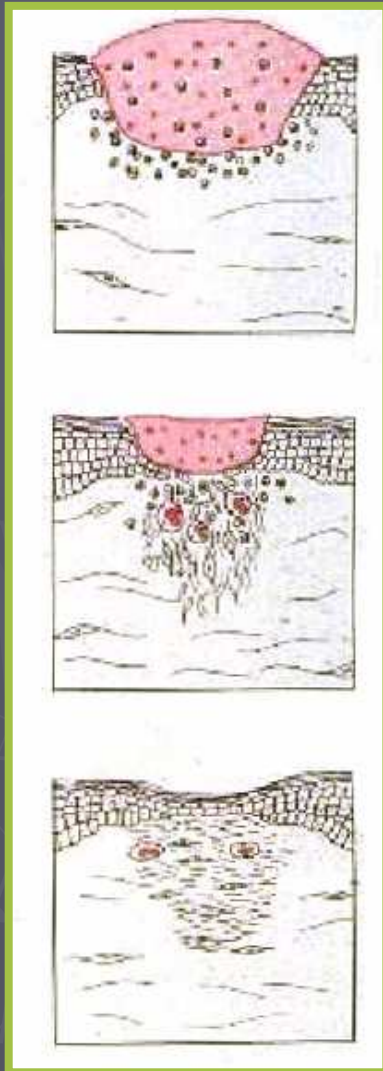


▶ *0-24^h: vérrög+ neutrophilek*

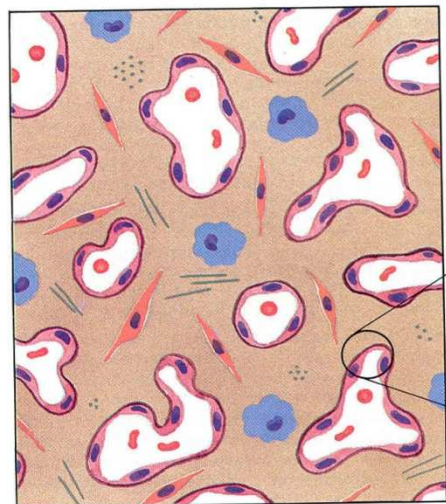
▶ *napok: granulatio szövet,
hámproliferáció*

▶ *Hetek: hegyszövet*

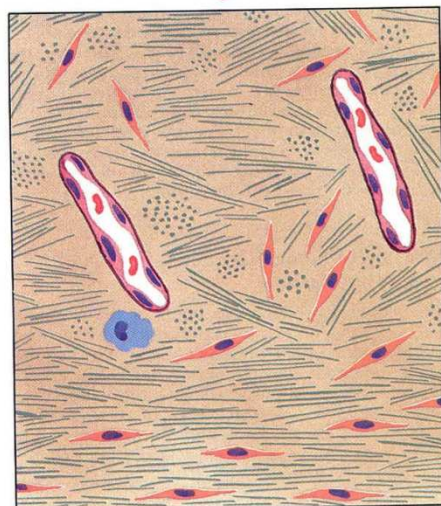Másodlagos sebgyógyulás



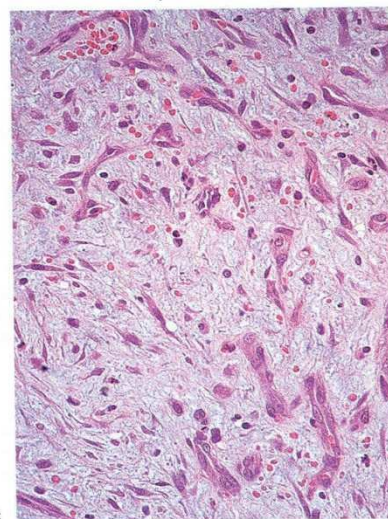
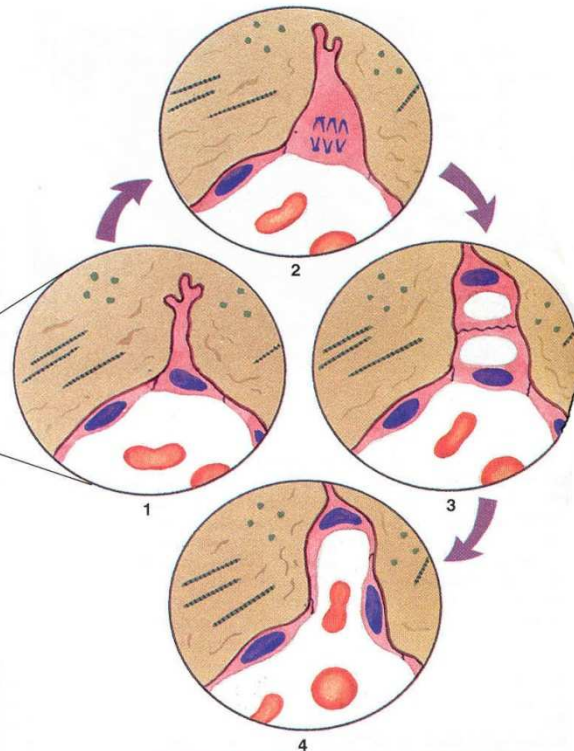
- ▶ ***0-24^h: necrosis, fibrin, gyulladákos sejtes exsudation***
- ▶ ***napok: granulatio szövet***
- ▶ ***hetek: kiterjedt heg, kontrakció....***



A

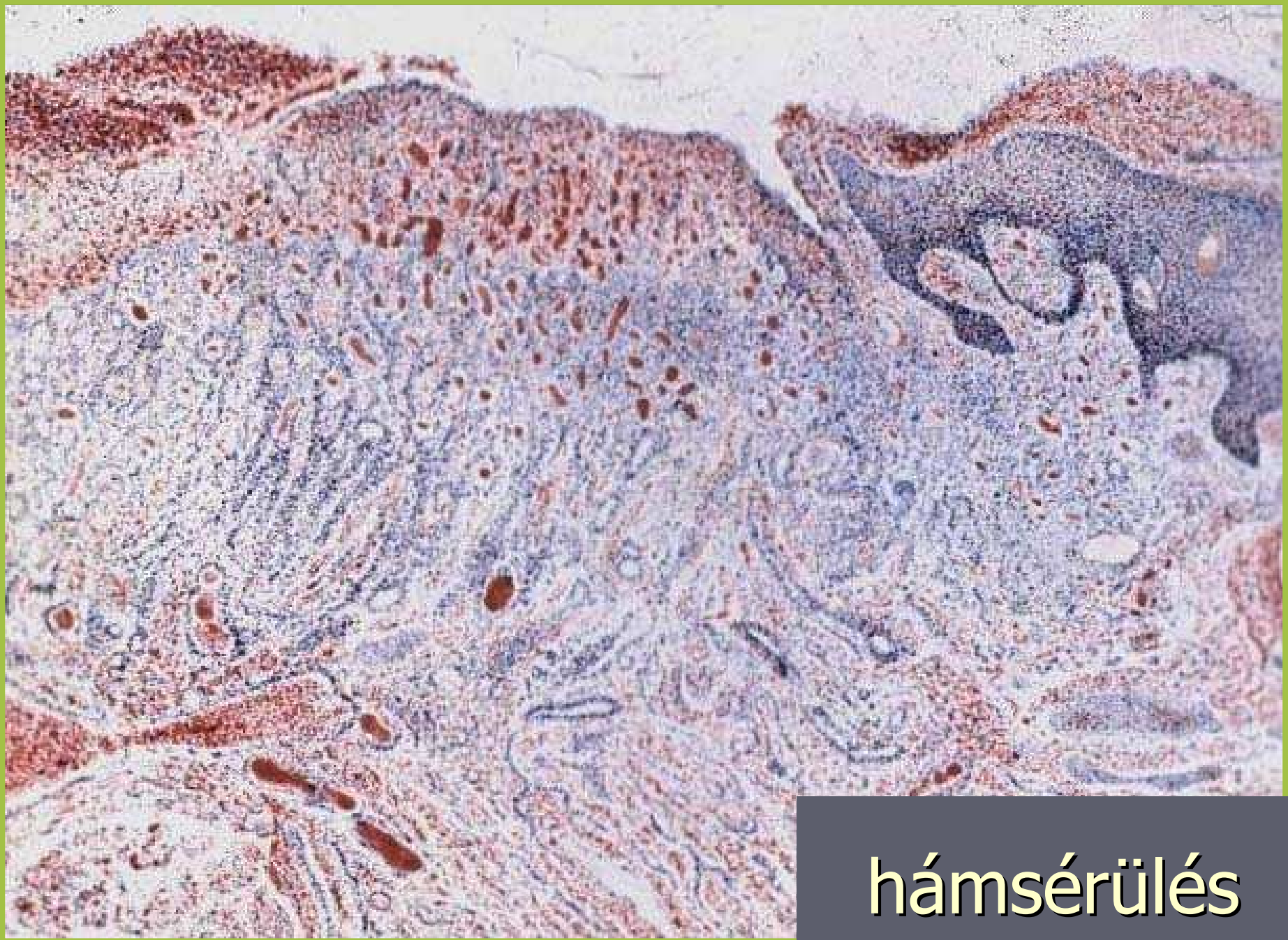


B

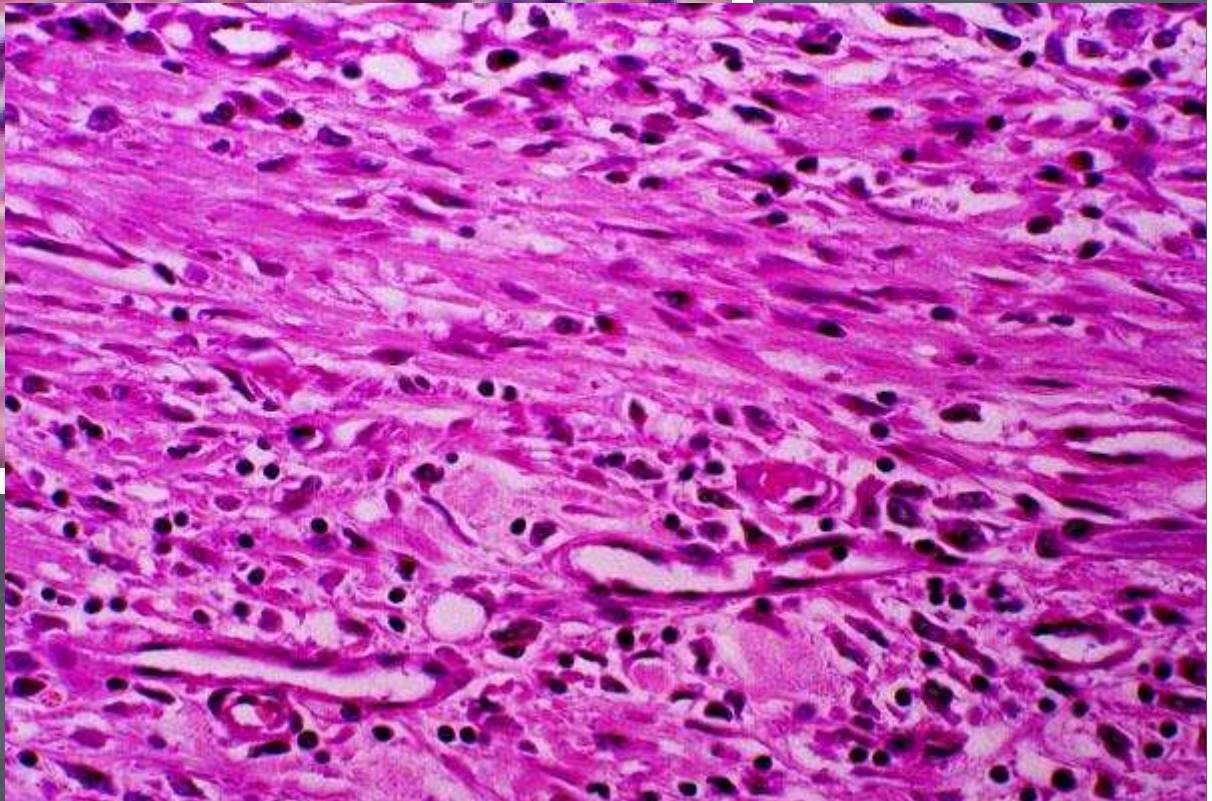
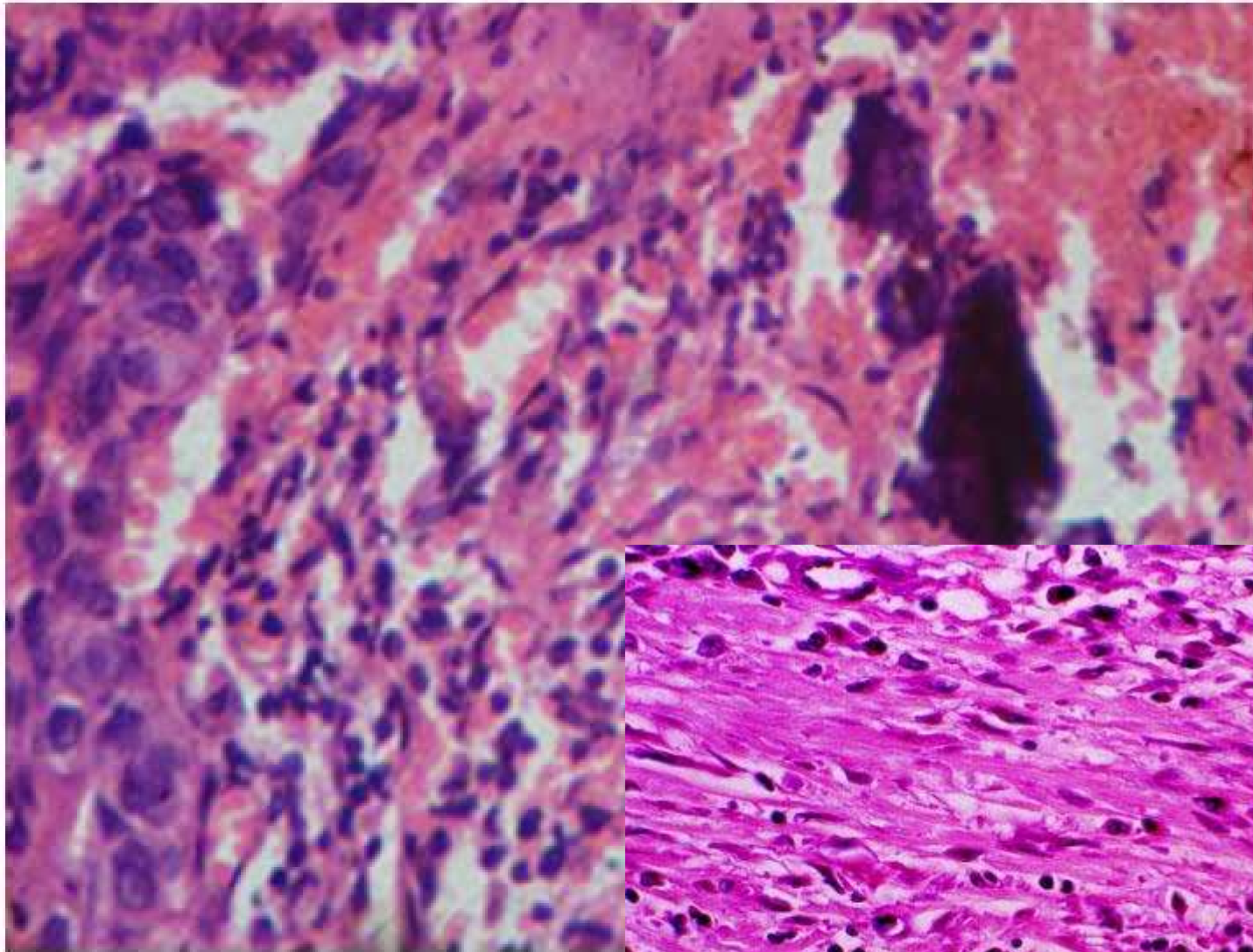


C

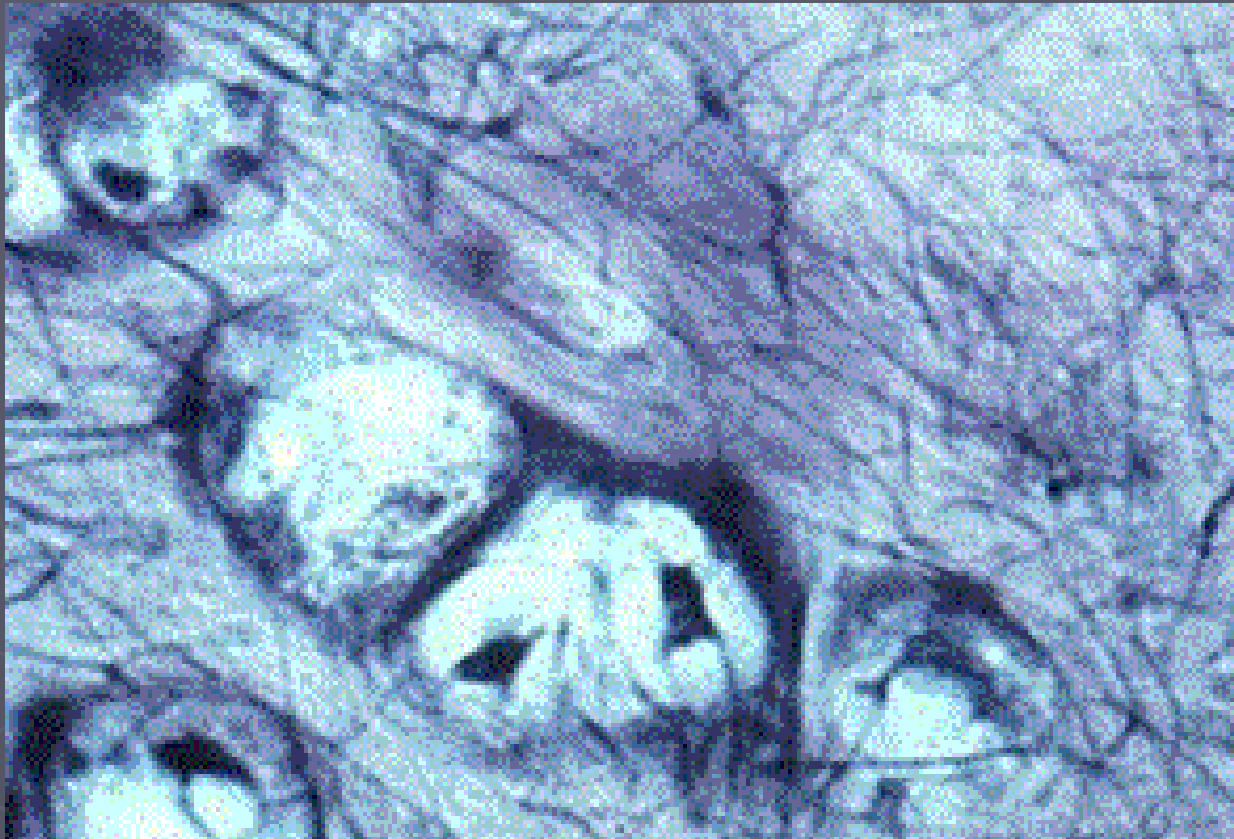
Granulációs
szövet ----
hegszövet



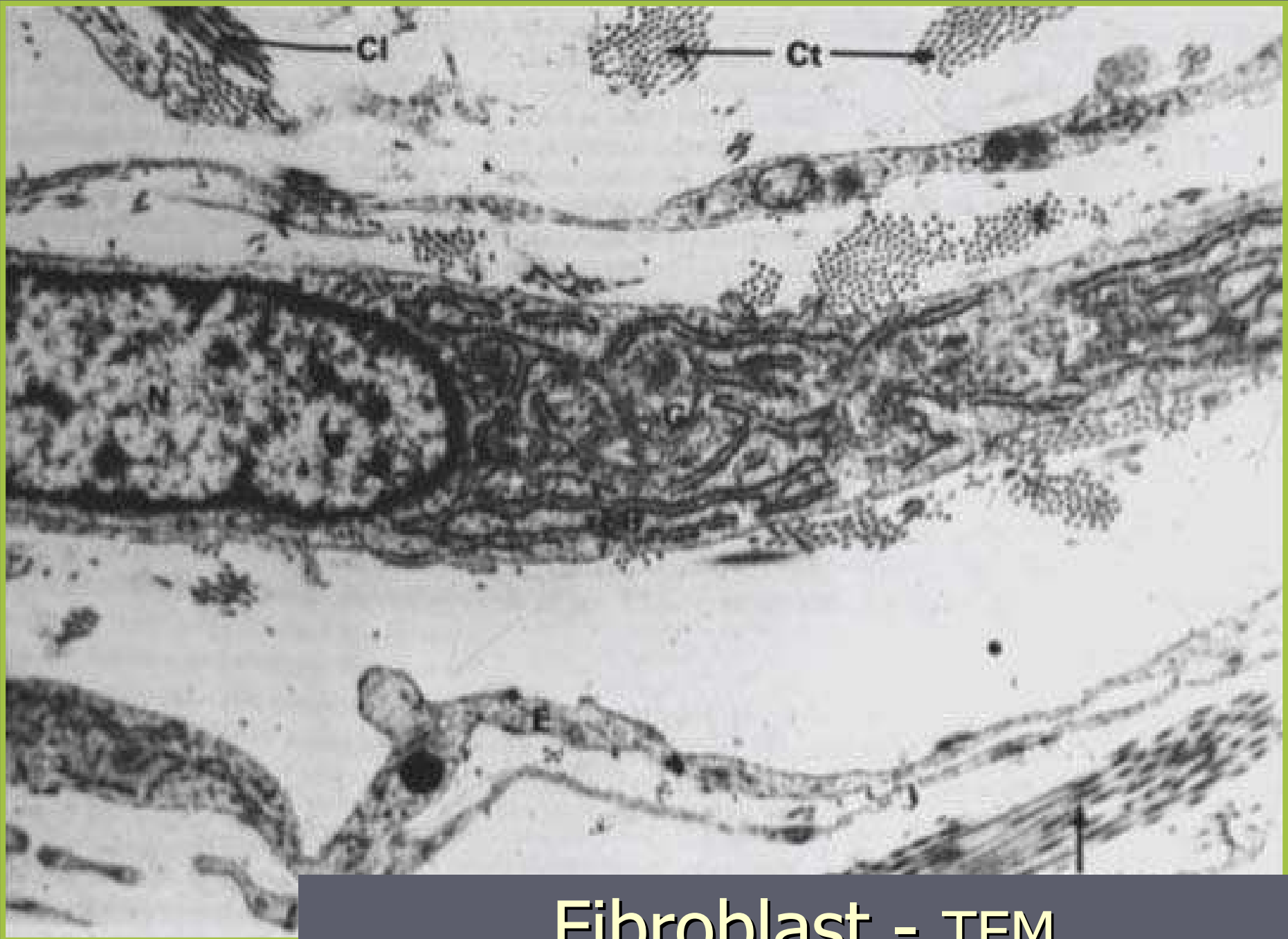hámsérülés



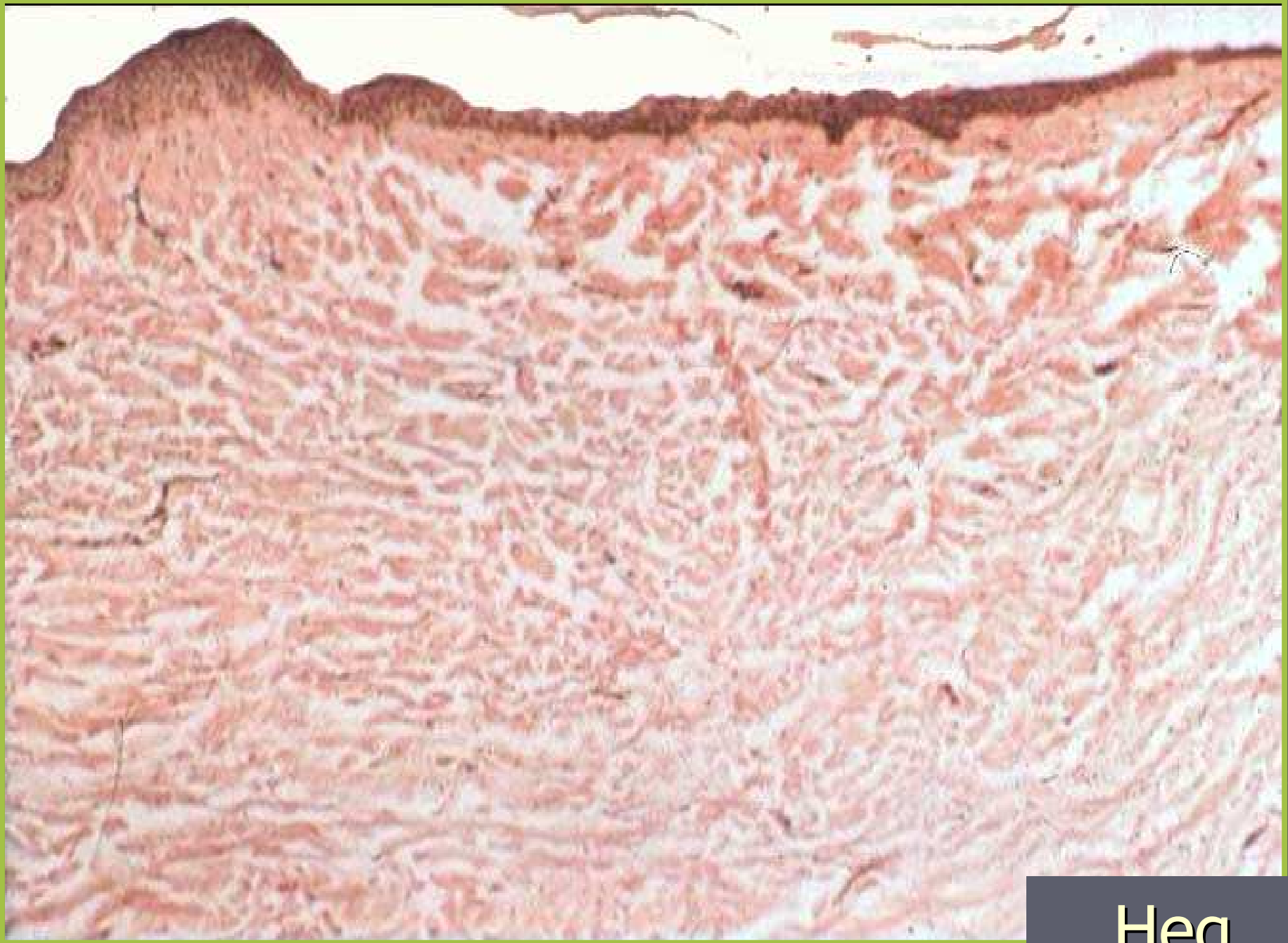
Granulatio



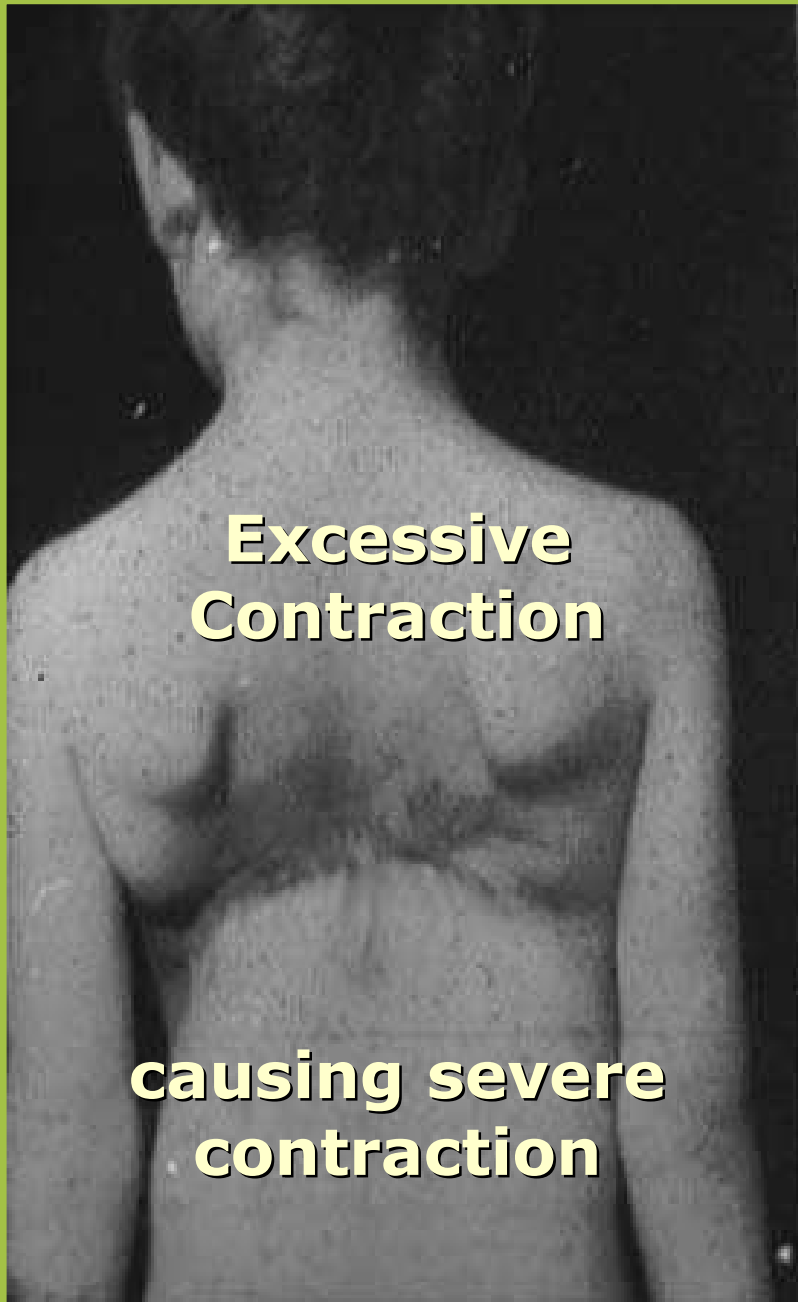
Heg - fibroblast



Fibroblast - TEM

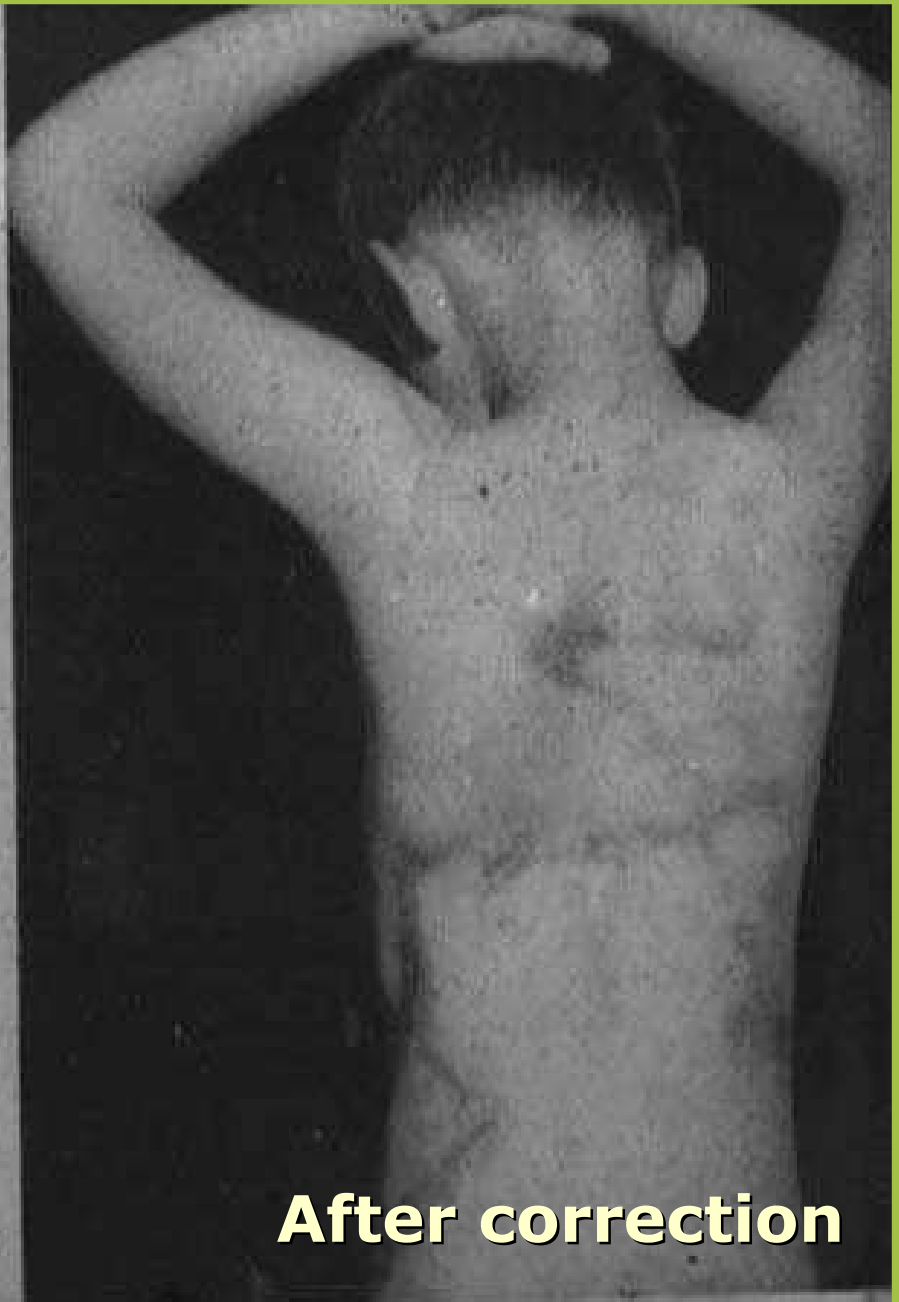

Heg



**Excessive
Contraction**

**causing severe
contraction**



After correction

Sebgyógyulást befolyásoló tényezők

helyi

Típus, méret, lokalizáció

sebészi, tramás

vérellátás

arc, láb

Infectio

késedelmes, deformáló heg

Irradiatio

gátolt regenerációs képesség

UV besugárzás

fokozott proliferáció

Sebgyógyulást befolyásoló tényezők

Szisztémás hatások

Kor

cardiovascularis status

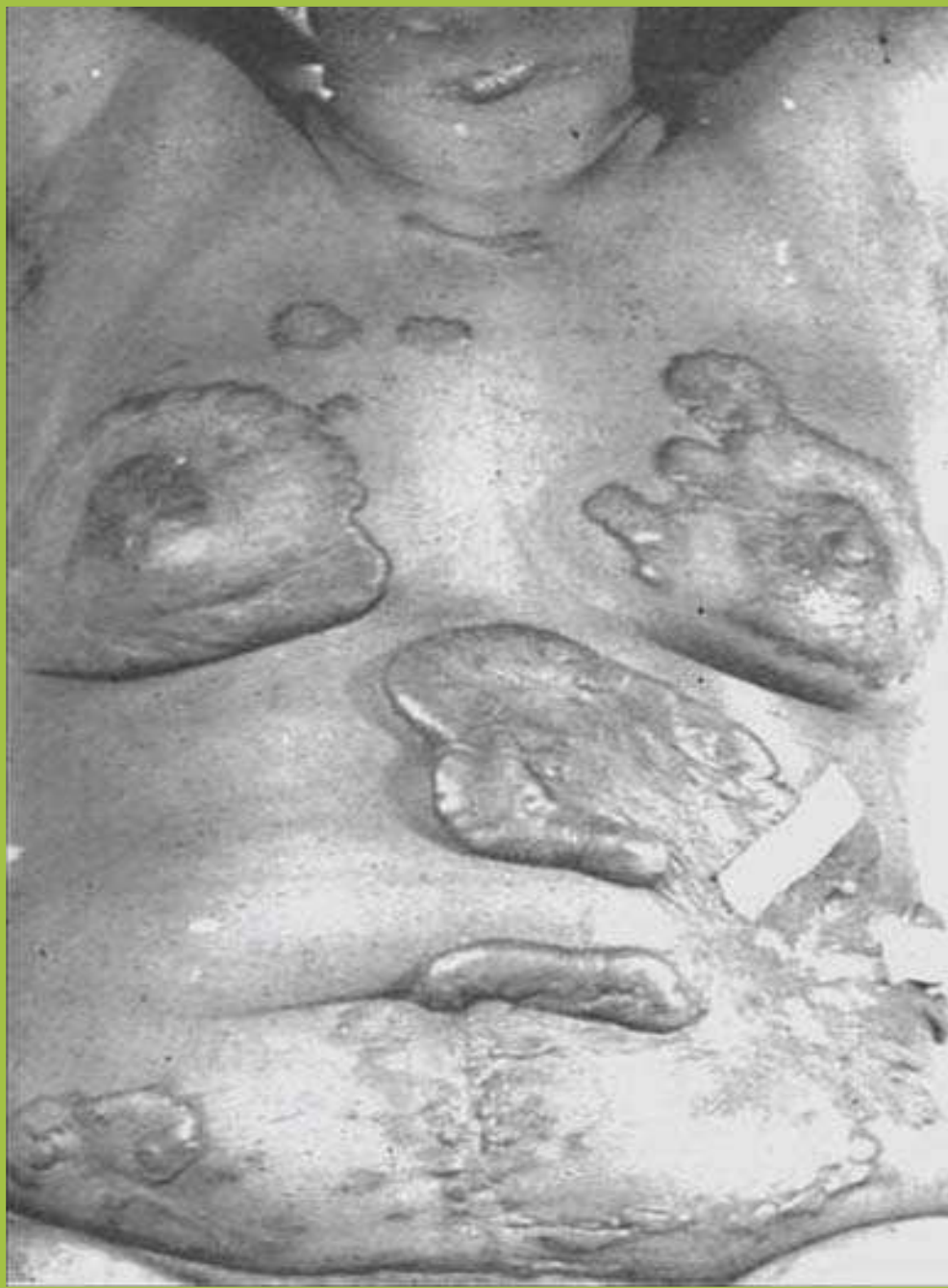Metabolikus status

diabetes infectio
hegszövettermelő képessé

Hormono

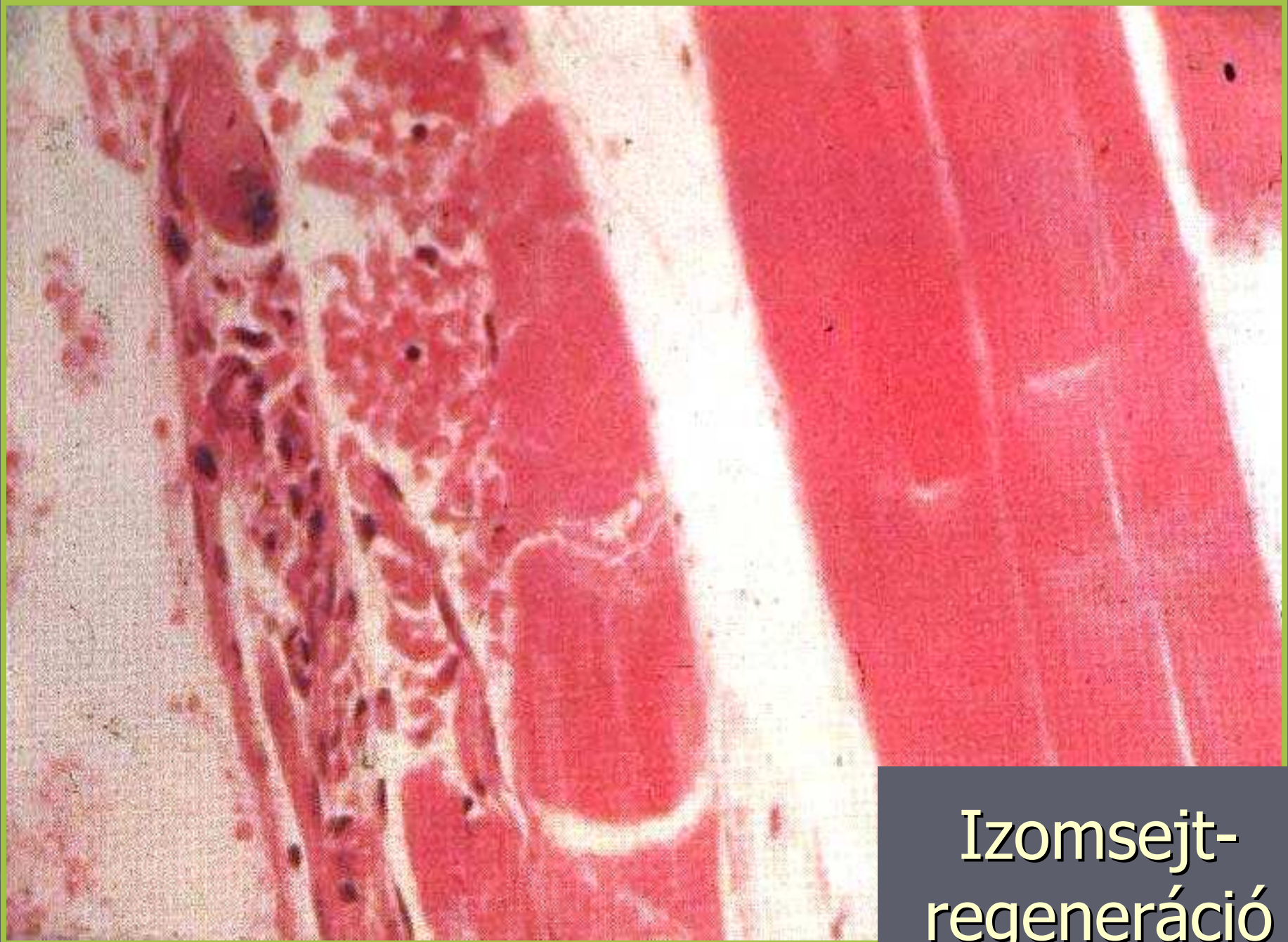
cortison, steroid,
gátolja a hegképződést

tiroxin
oestrogen indirekt hatások
androgen

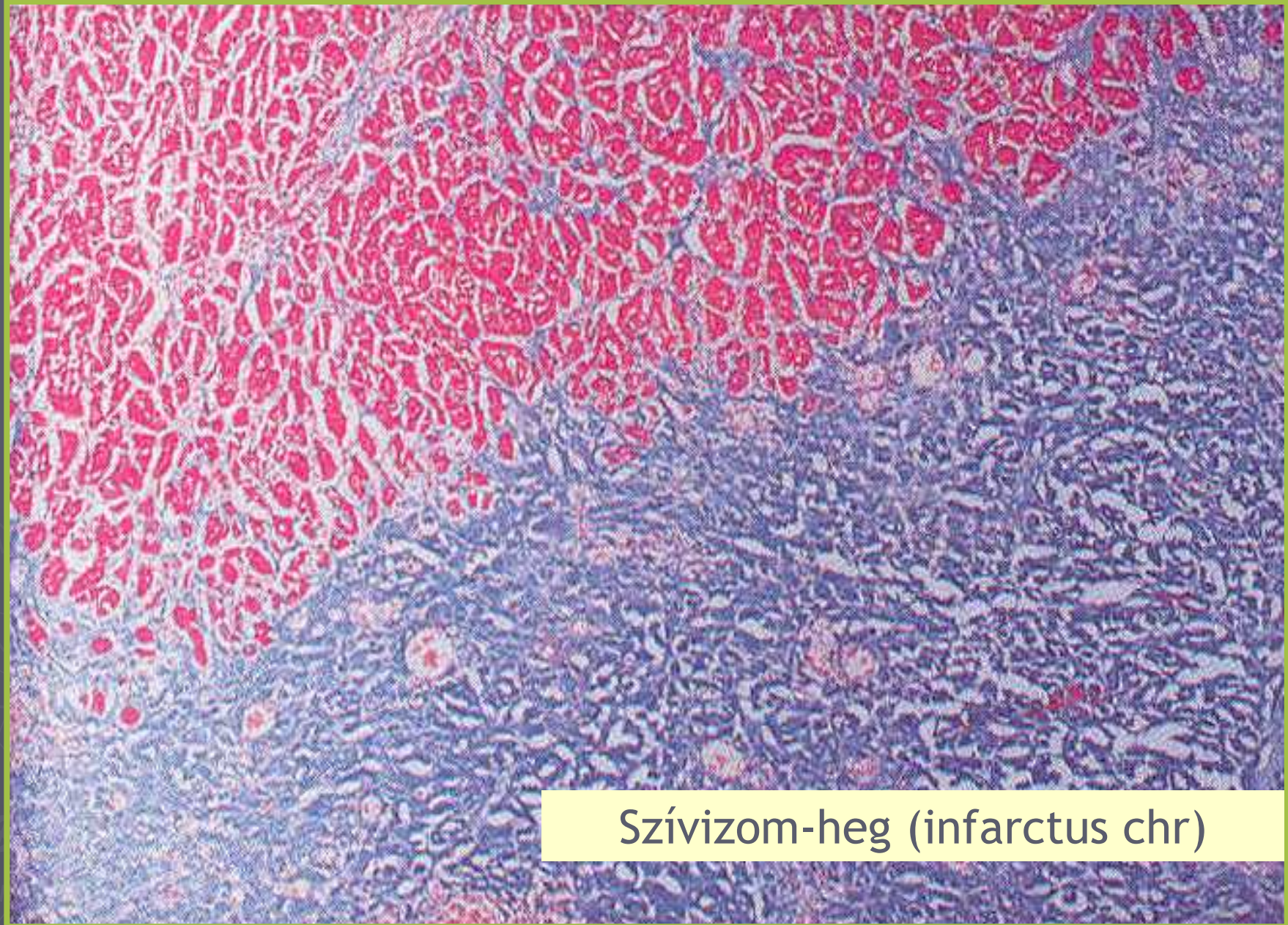

KELOID

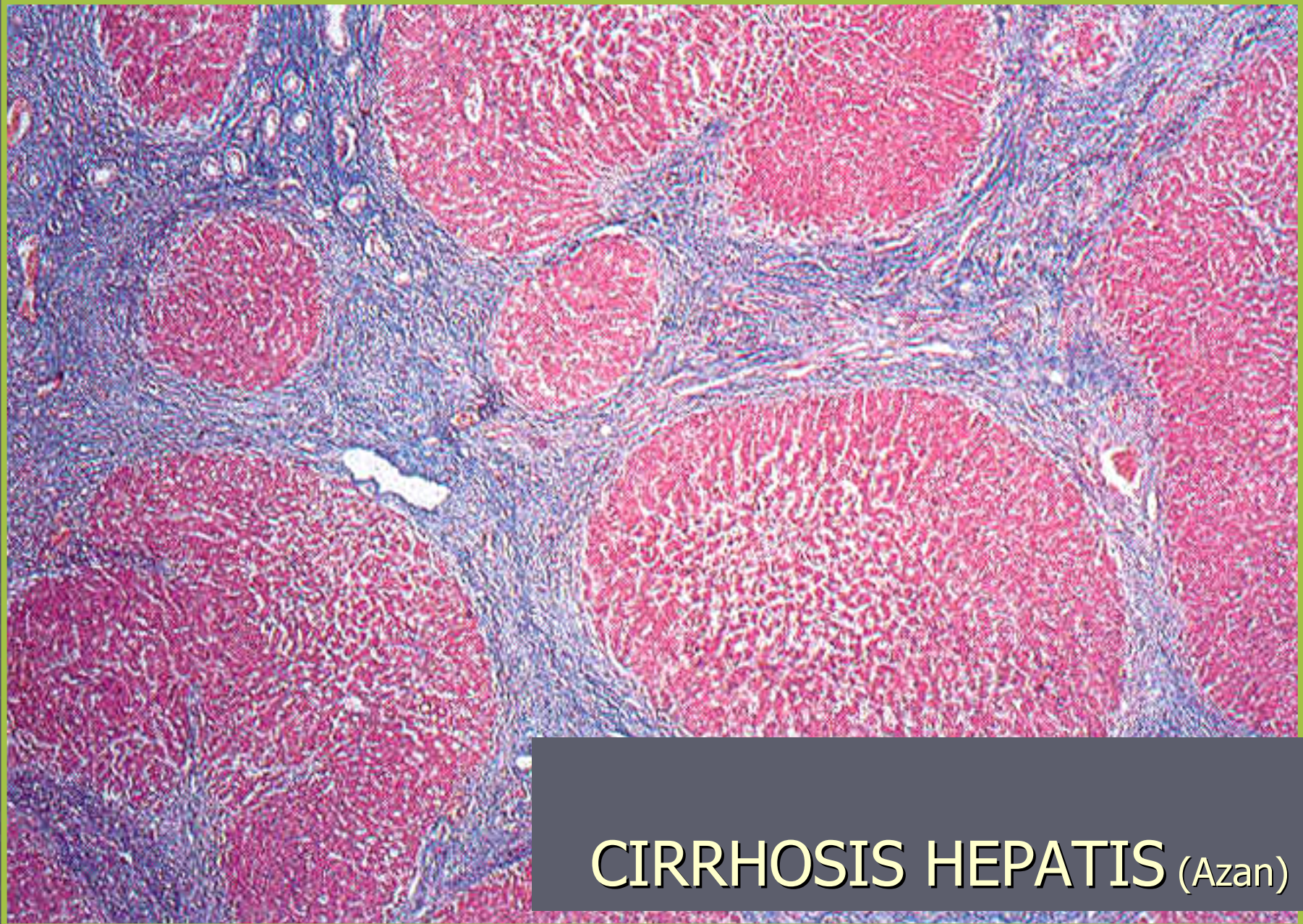
*A sebzés
helyén
excesszív
hegszövet
képződése*



Izomsejt-
regeneráció



Szívizom-heg (infarctus chr)



CIRRHOSIS HEPATIS (Azan)

Csontregeneráció

