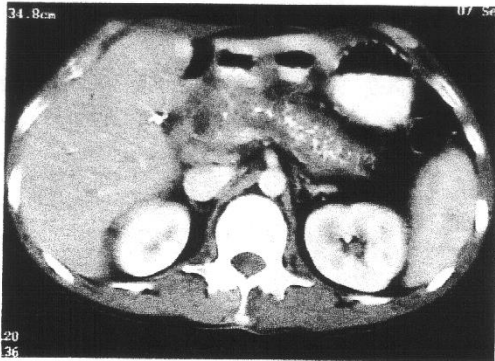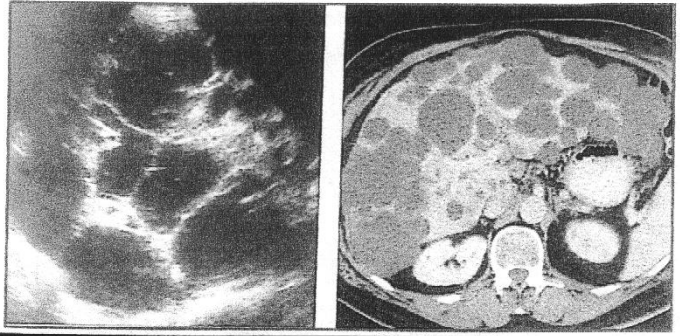
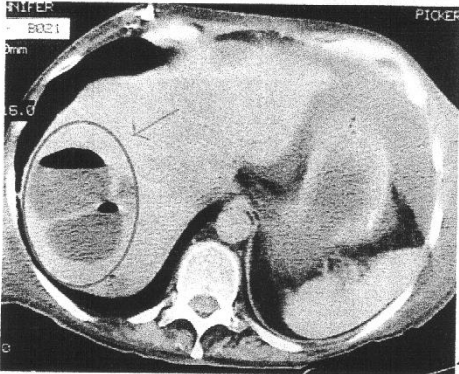


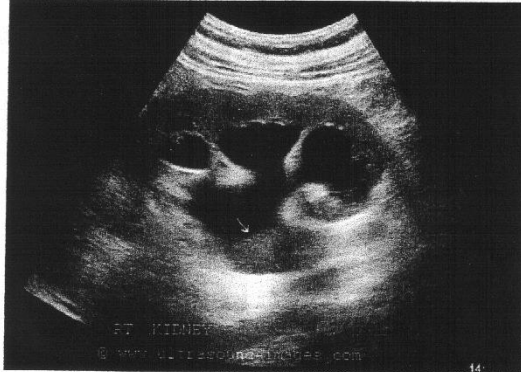9.



10.

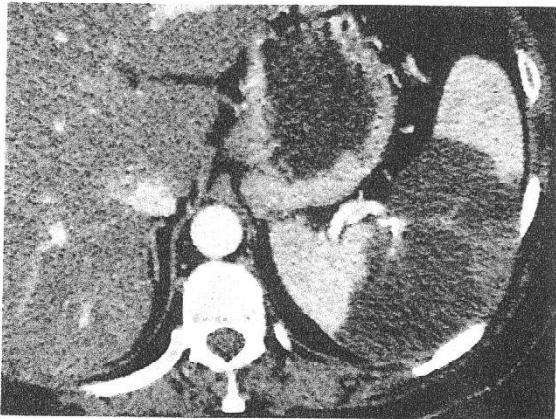


11.

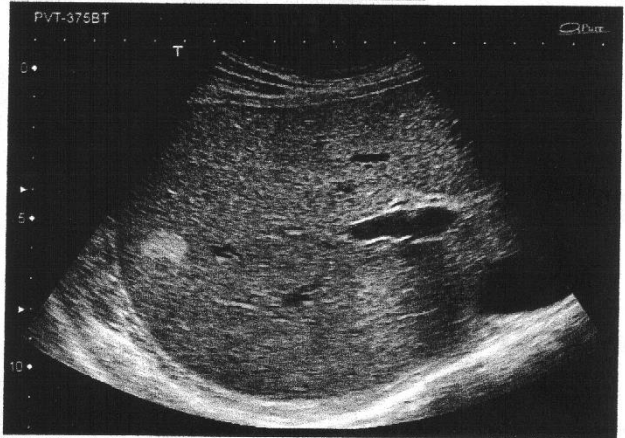


12.

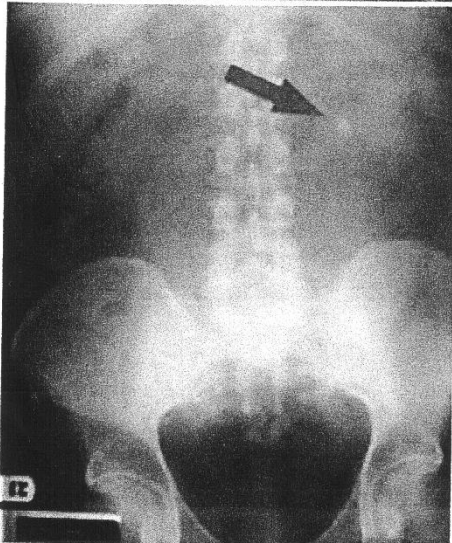
9. CT, pancreas
 krónikus pancreai
 10. UH, B-Mód + CT, n
 polycystás máj
 11. CT, máj, absz
 12. UH, B-Mód, ves-
 nephrolithiasis
 13. CT, lép, lépíng
 14. UH, B-Mód, máj
 haemangioma



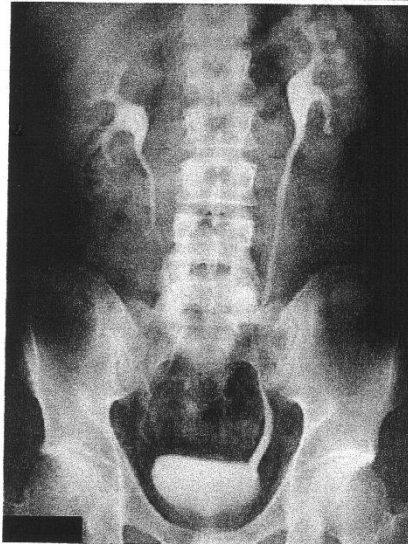13.



14.



15.



16.

15. hasi rtg P-A, vesék
 nephrolithiasis ✓
 16. kontrasztanyag hasi
 rtg P-A, vesemedence + uret

sr. nephria
 monnalis radialis uretalis

Nepou p! Uges vgr! :)