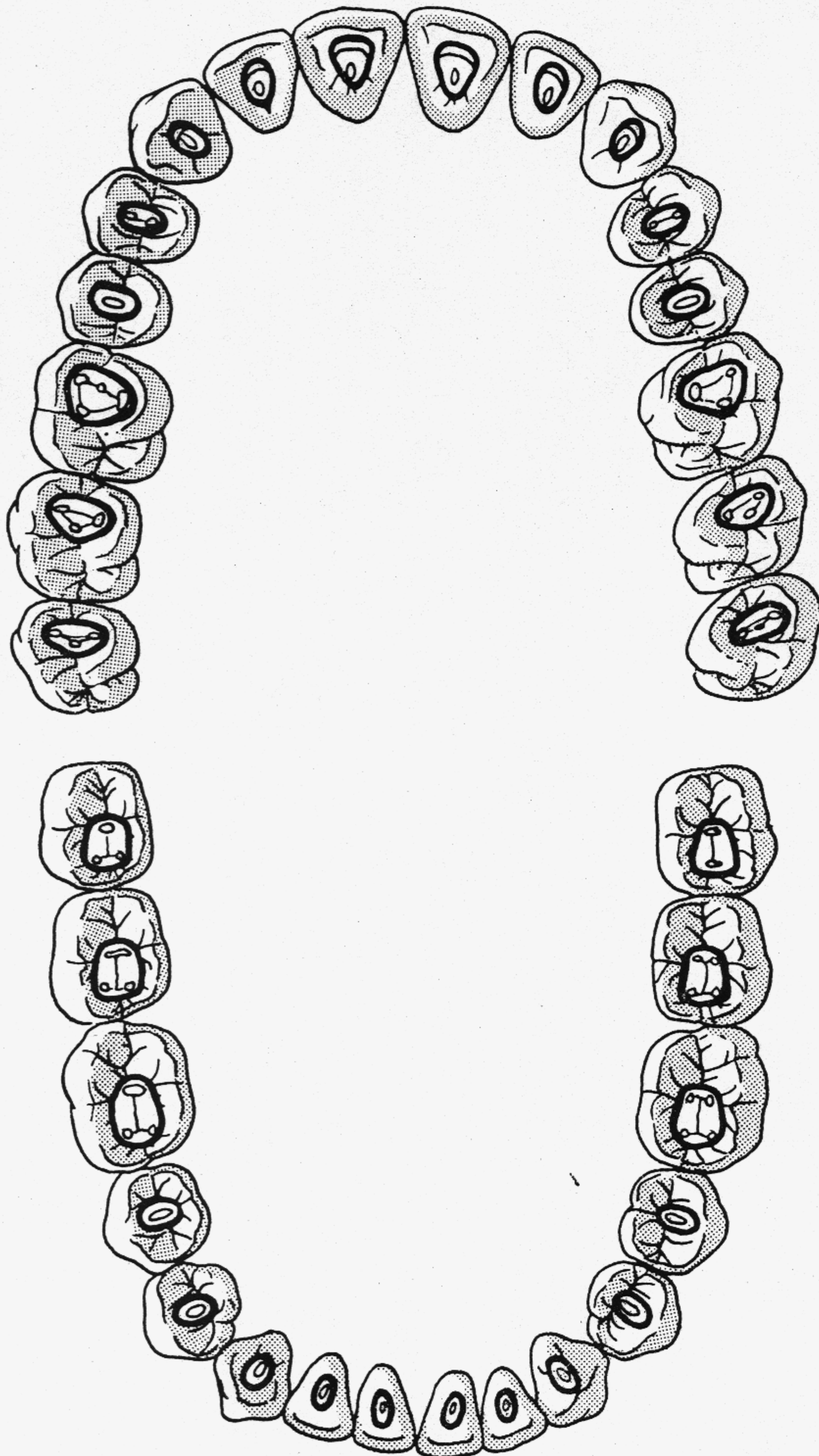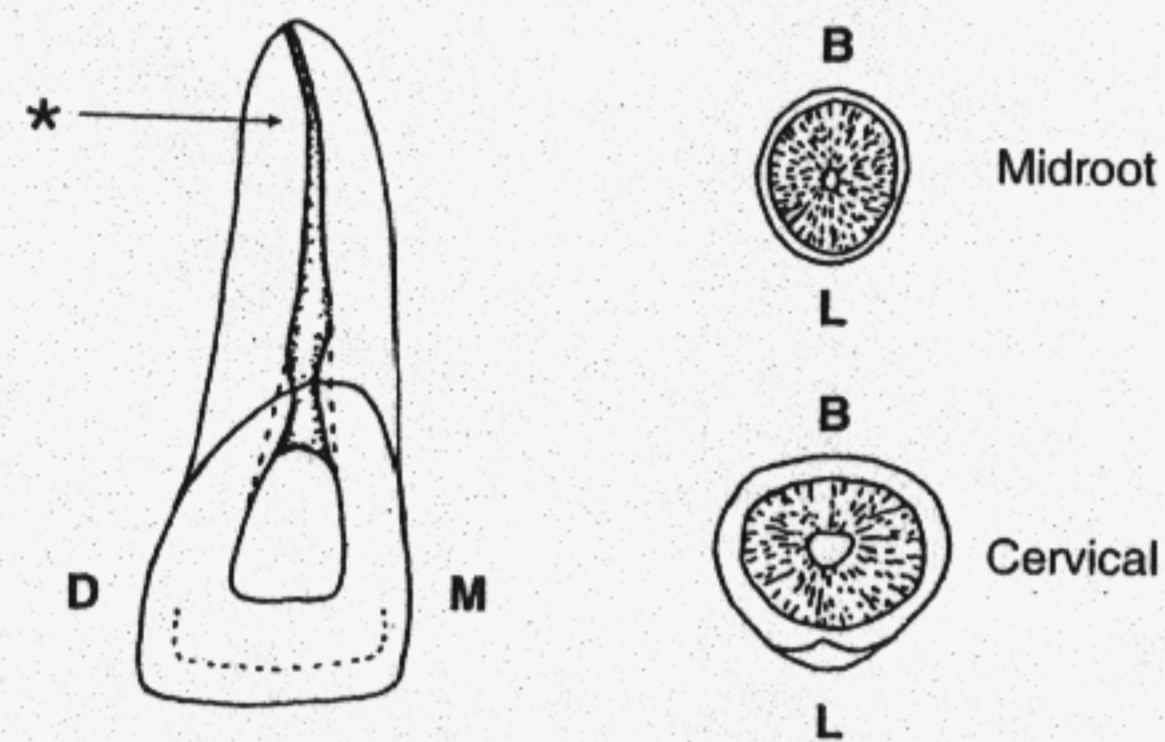
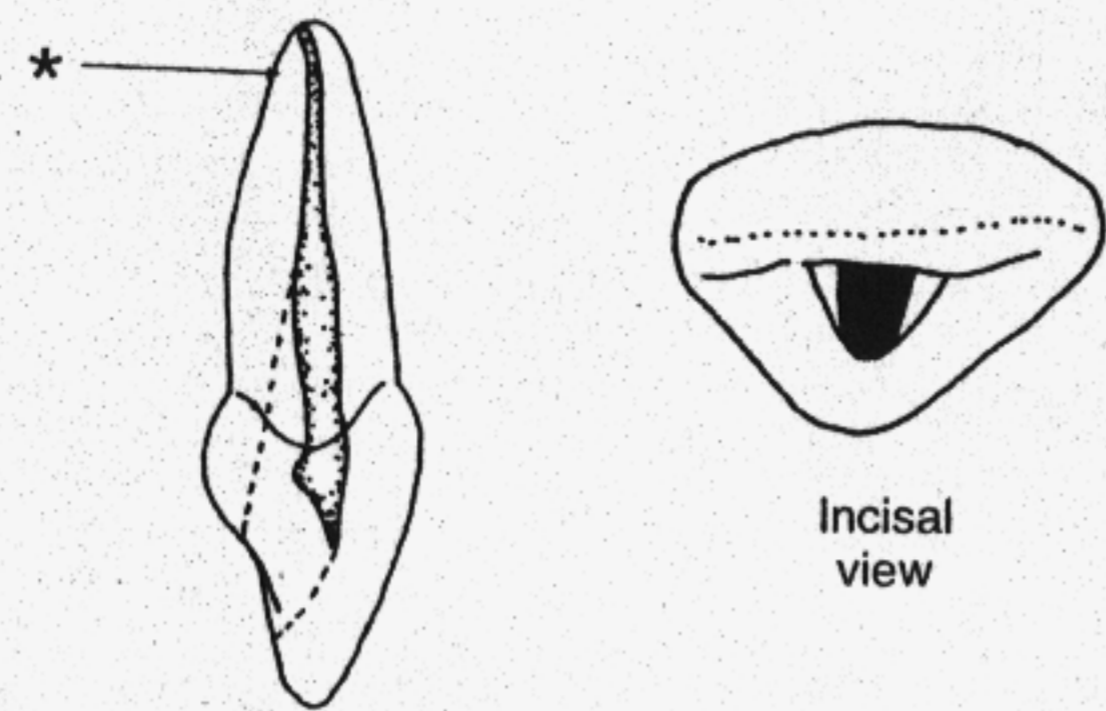


Fig. 6-1. Outline of ideal access cavities.

Maxillary Right Central Incisor

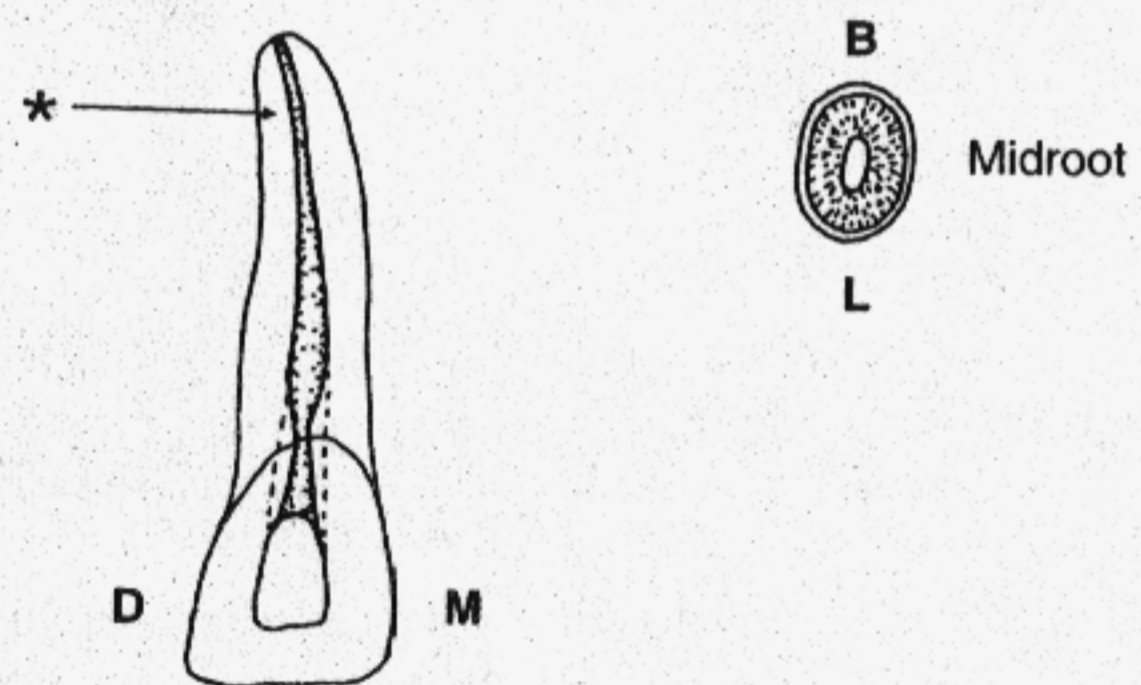


*Most common root curvatures

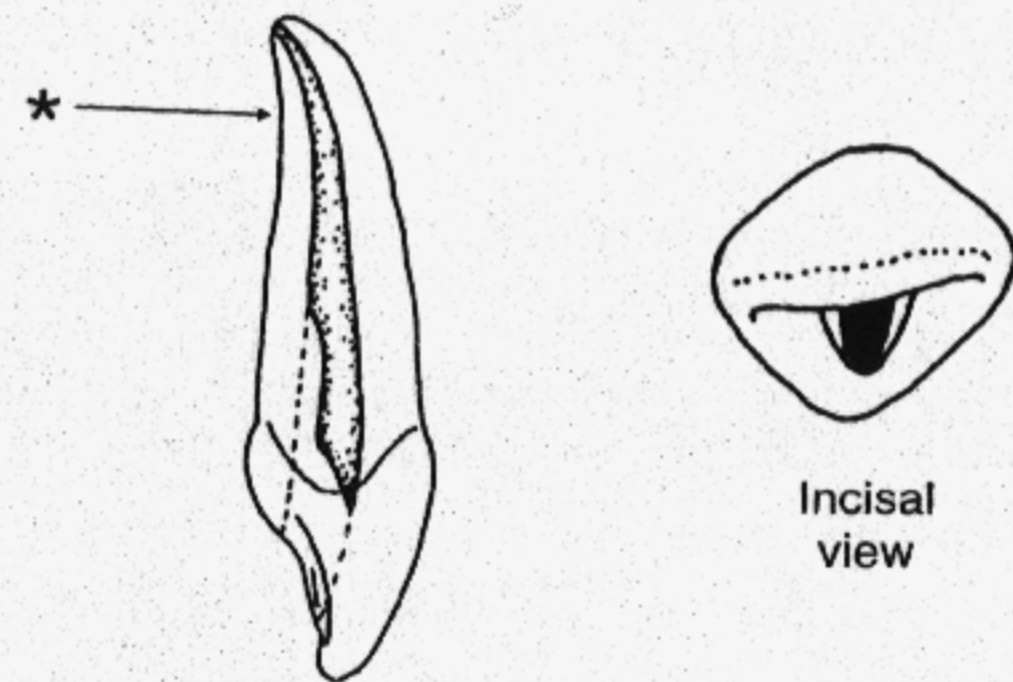


1 canal: 100%

Maxillary Right Lateral Incisor

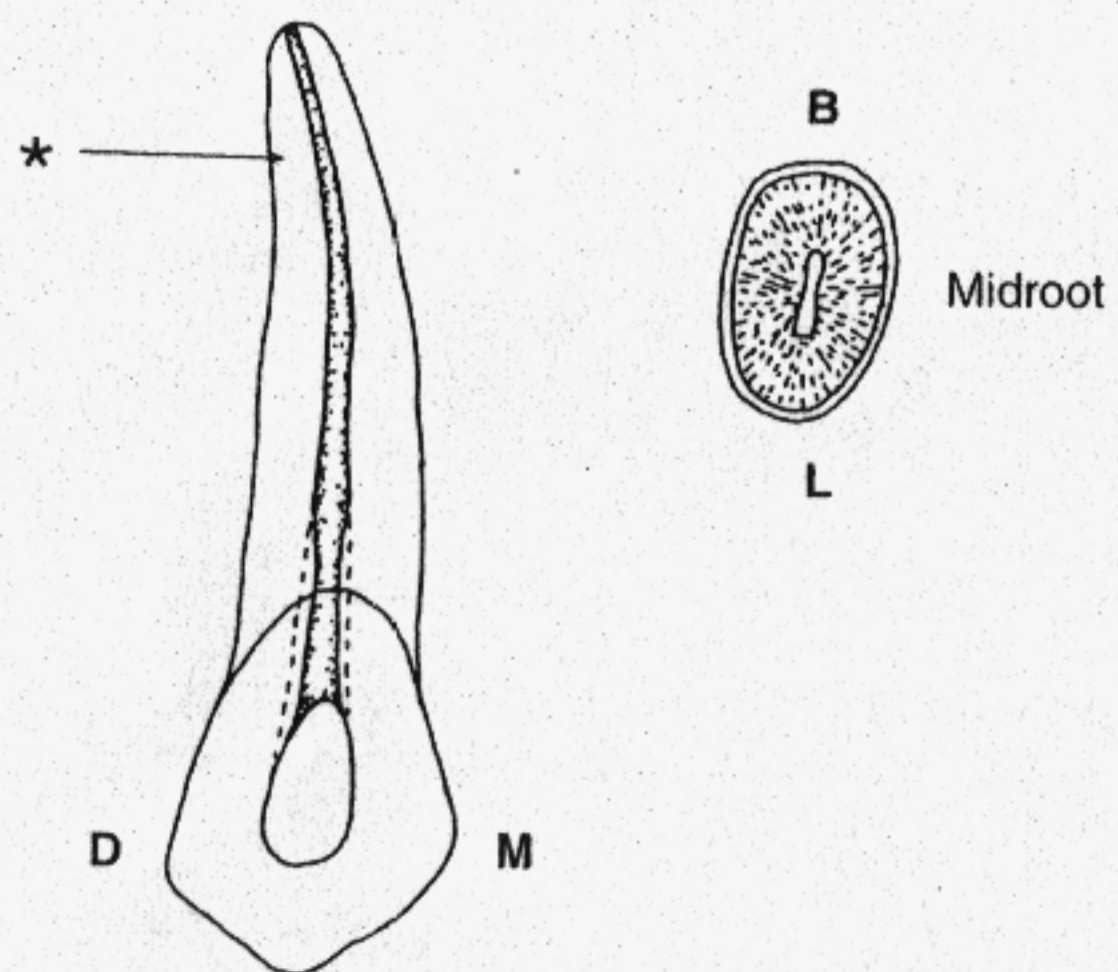


*Most common root curvatures

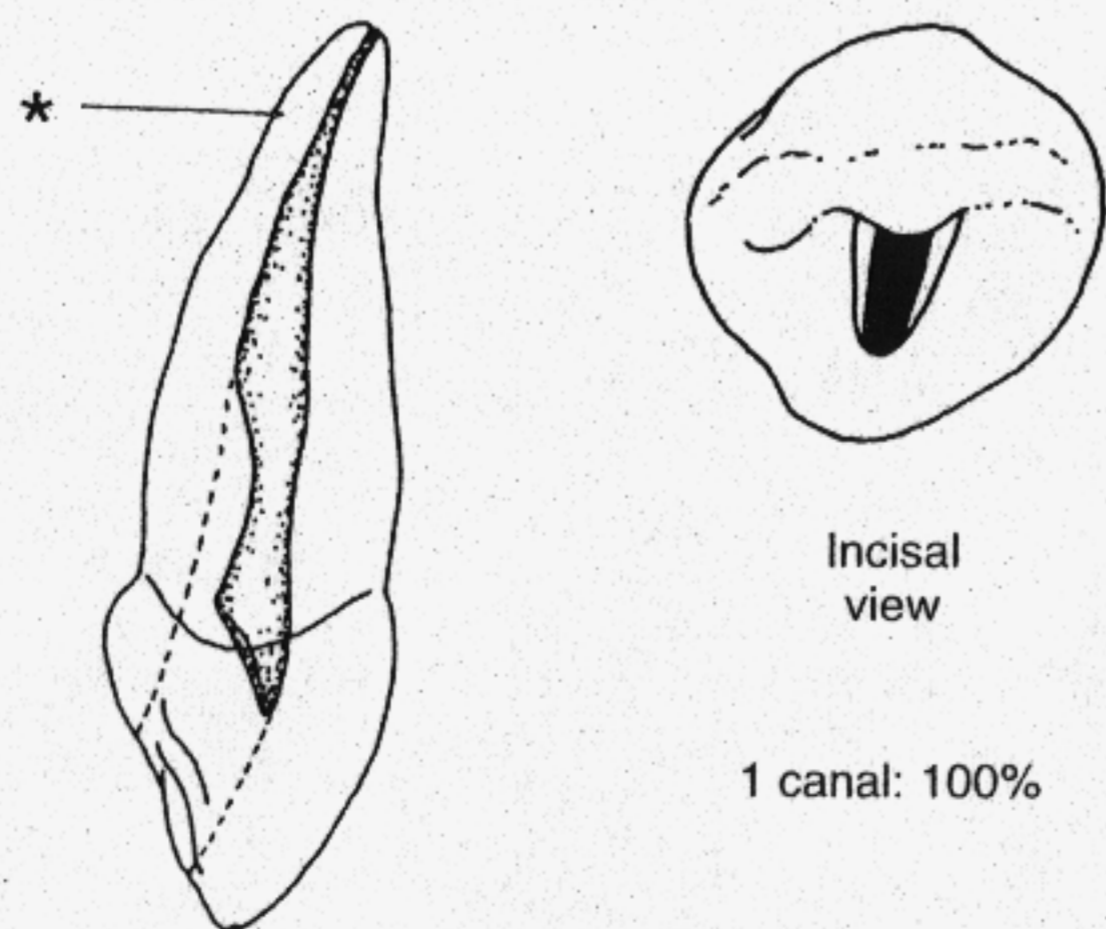


1 canal: 100%

Maxillary Right Canine

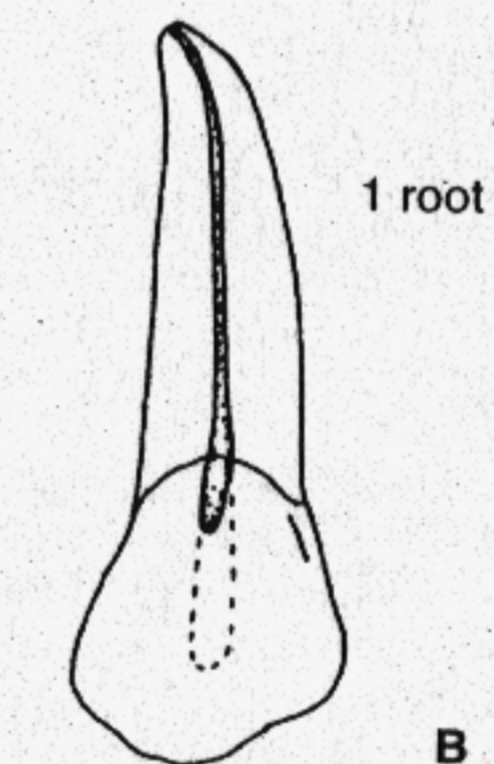
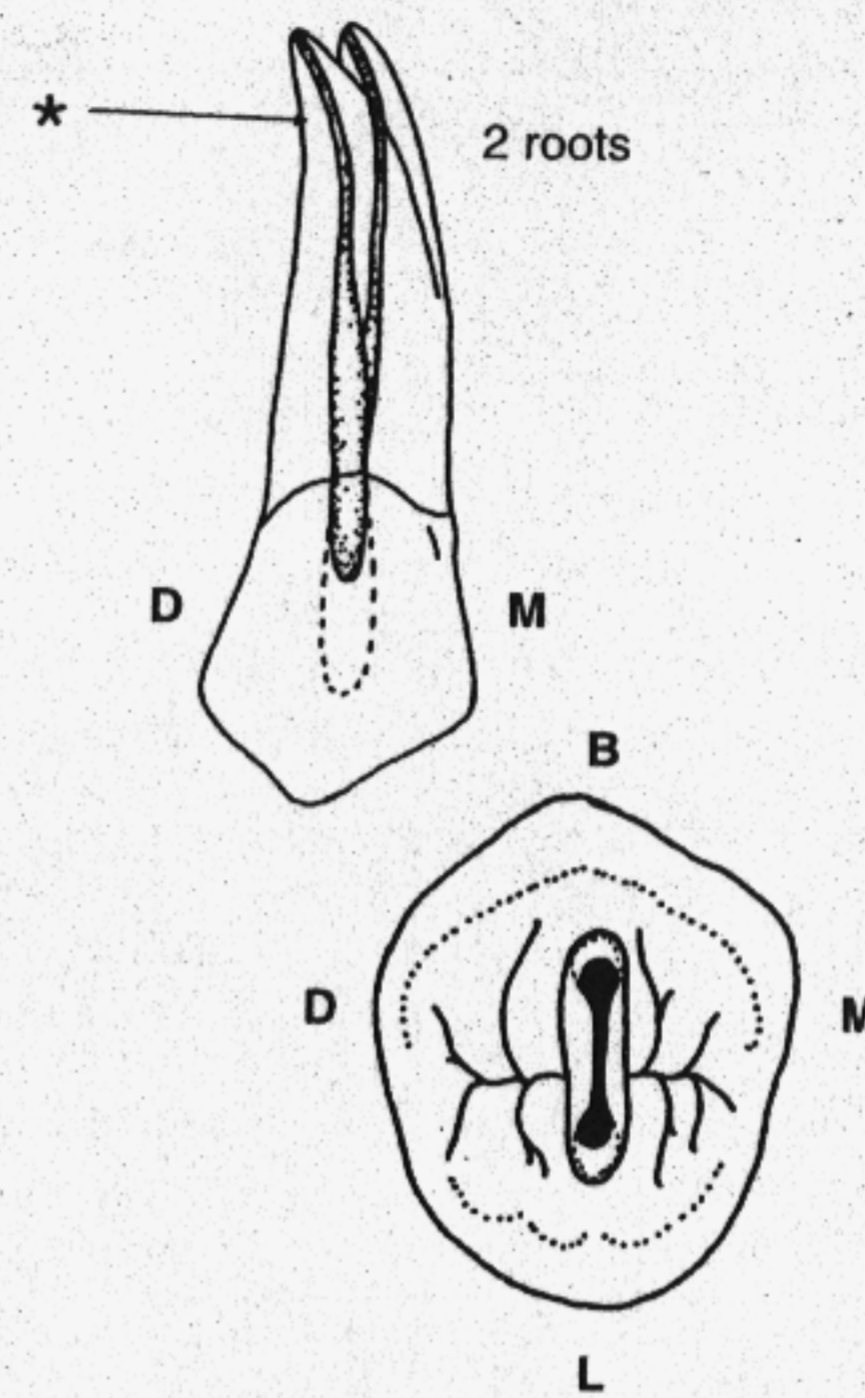


*Most common root curvatures

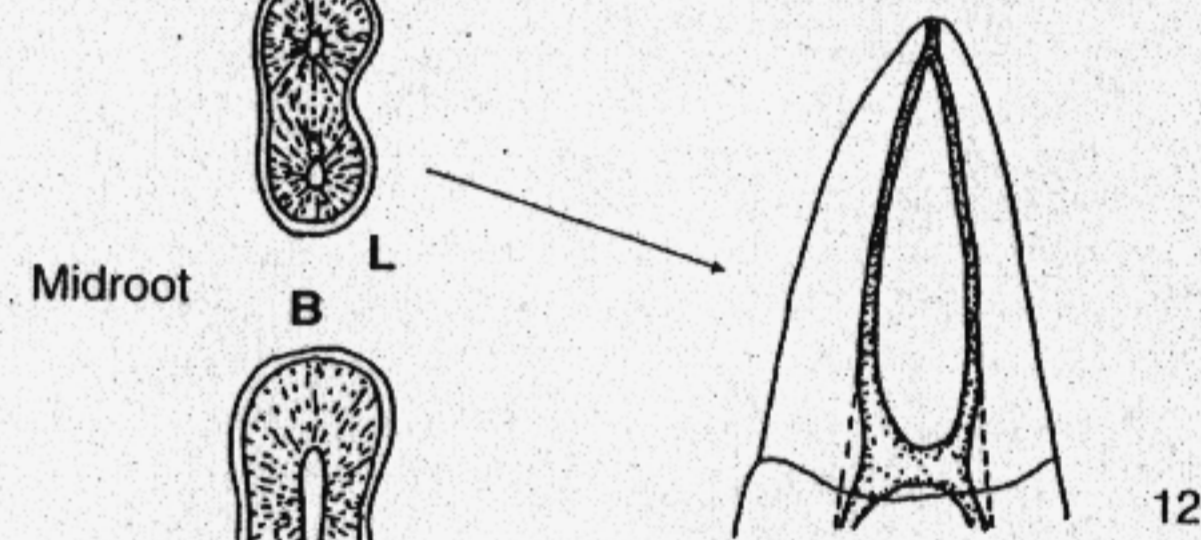
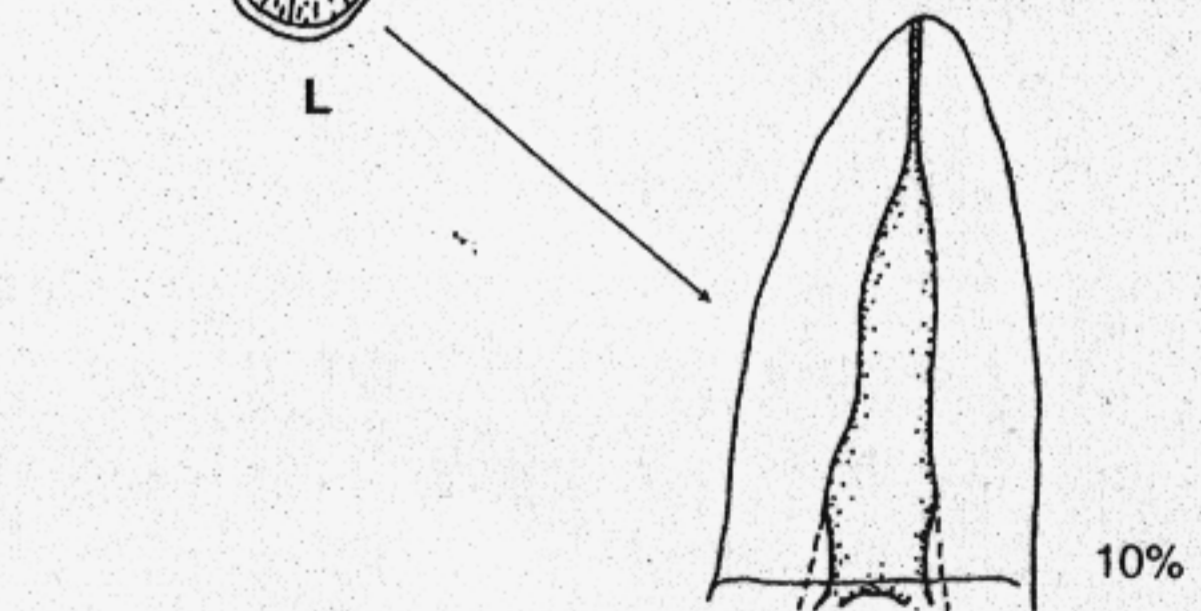
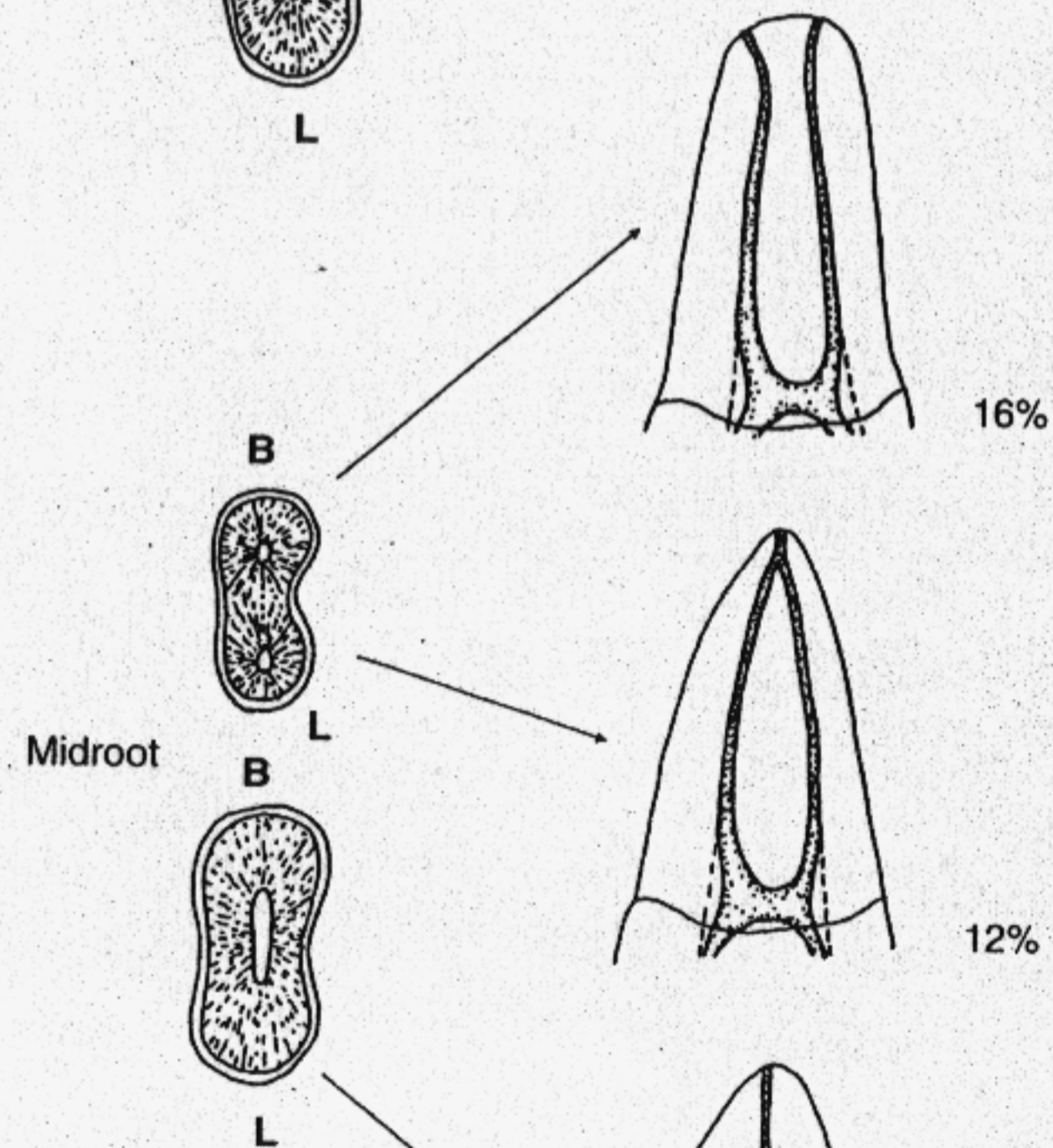
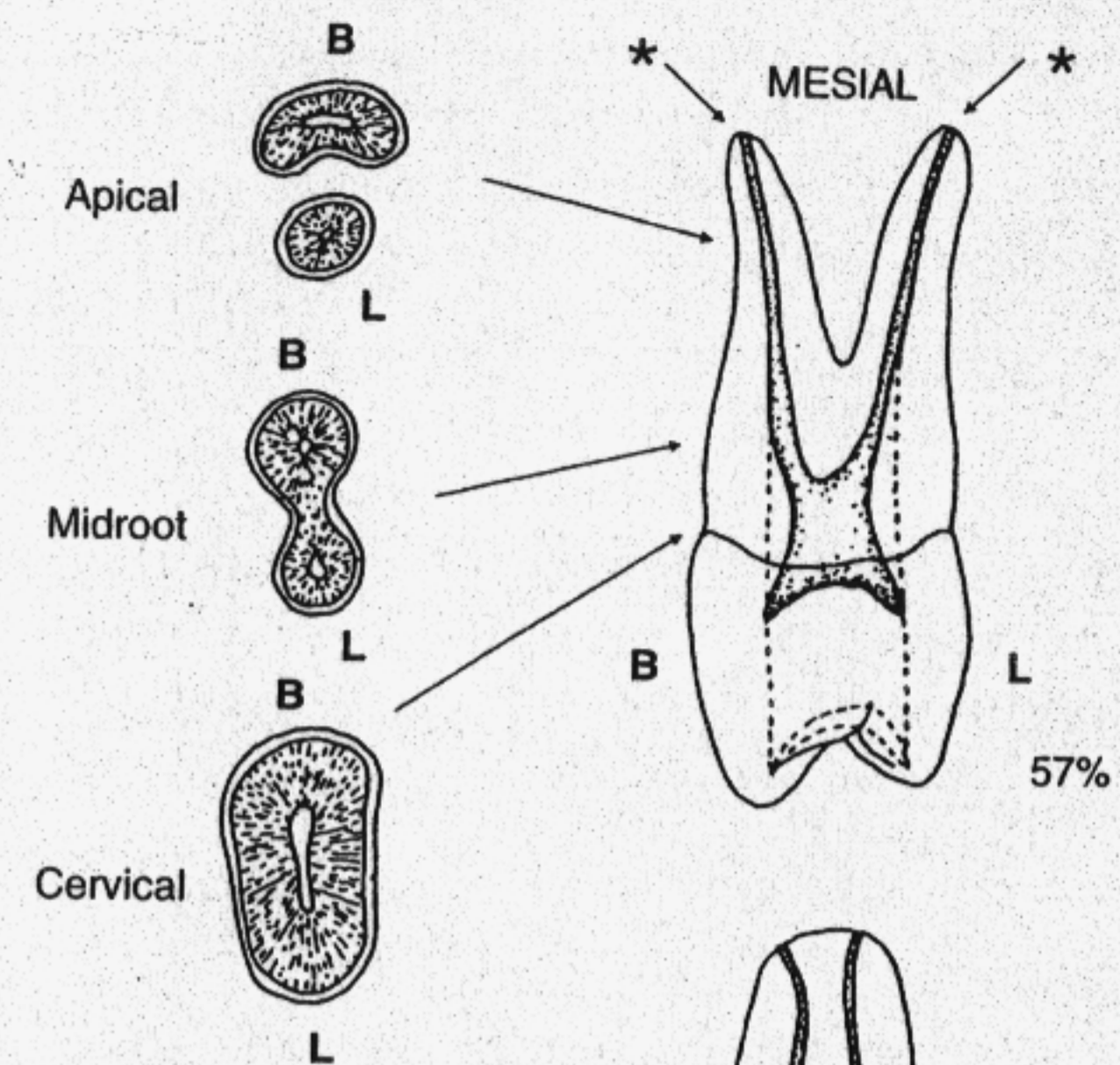


1 canal: 100%

Maxillary Right First Premolar

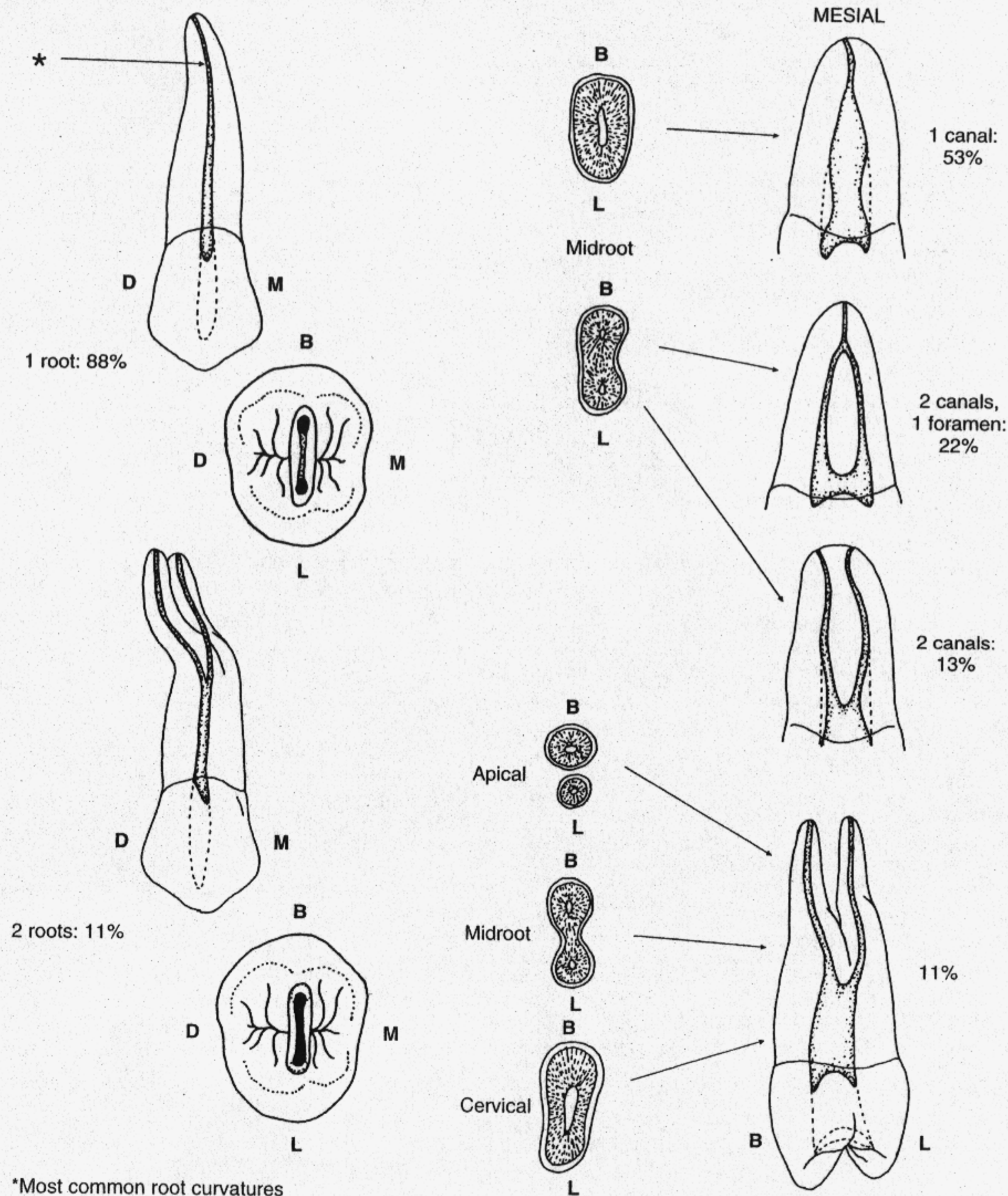


*Most common root curvatures



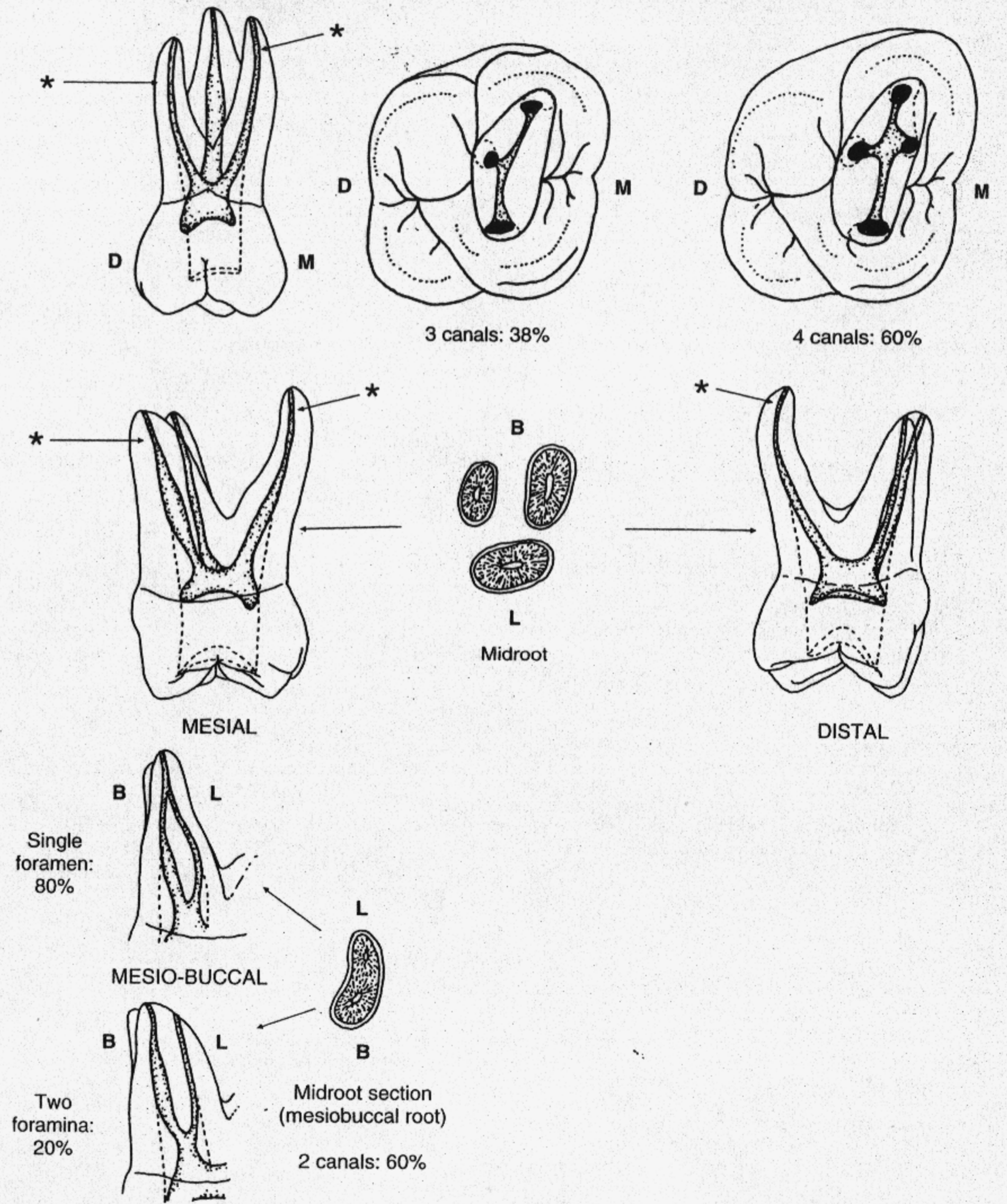
10%

Maxillary Right Second Premolar



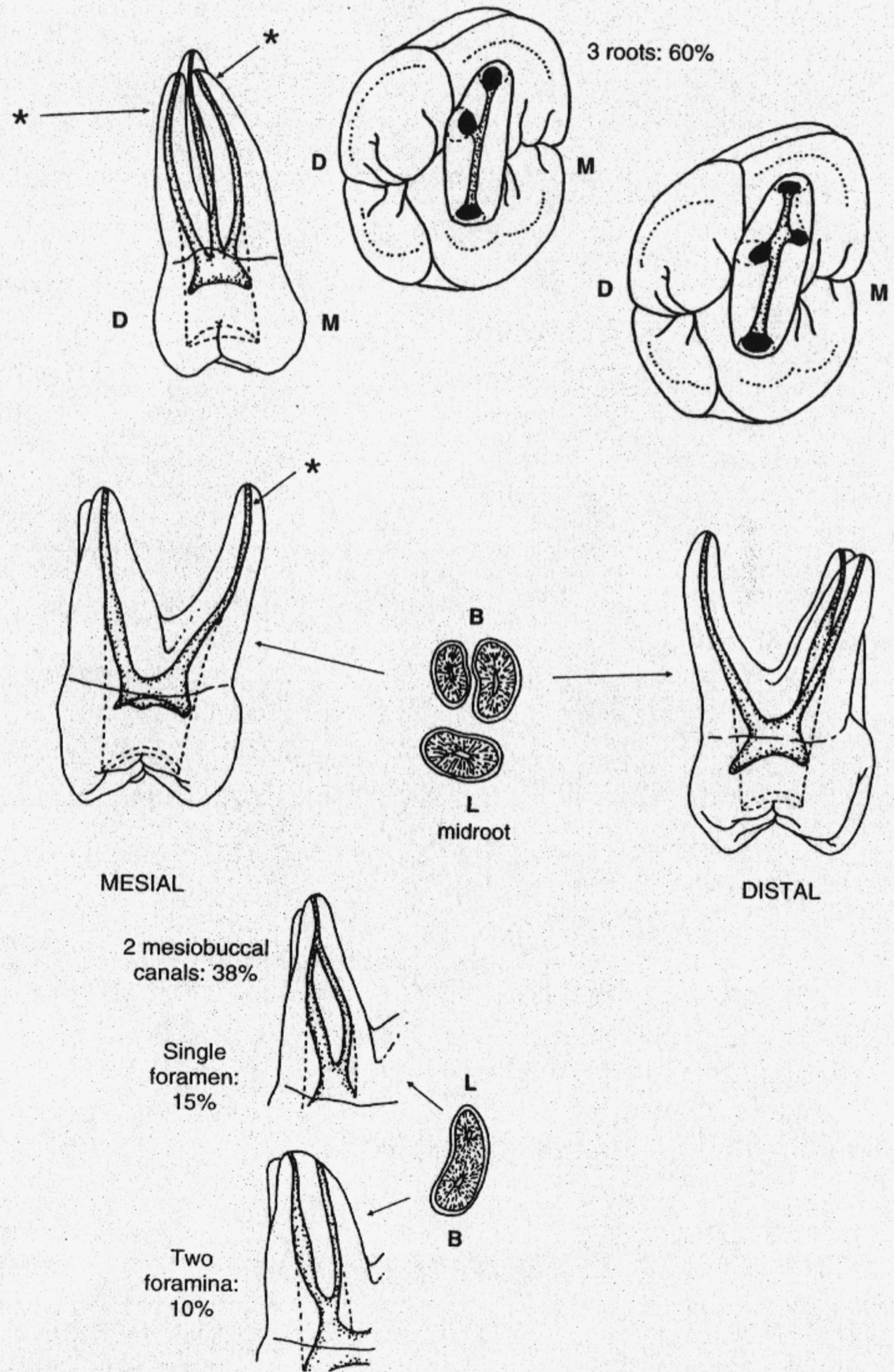
*Most common root curvatures

Maxillary Right First Molar

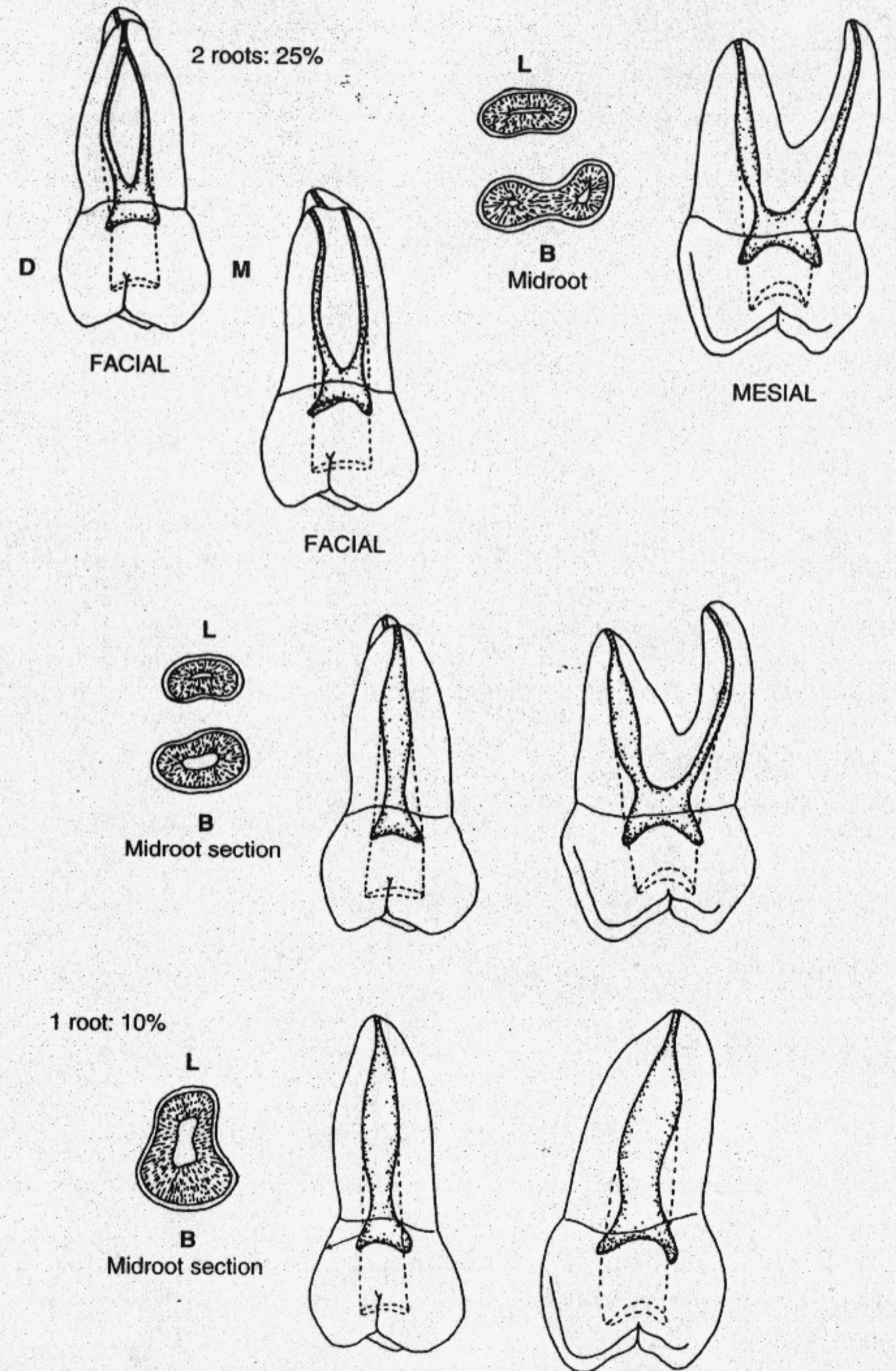


*Most common root curvatures

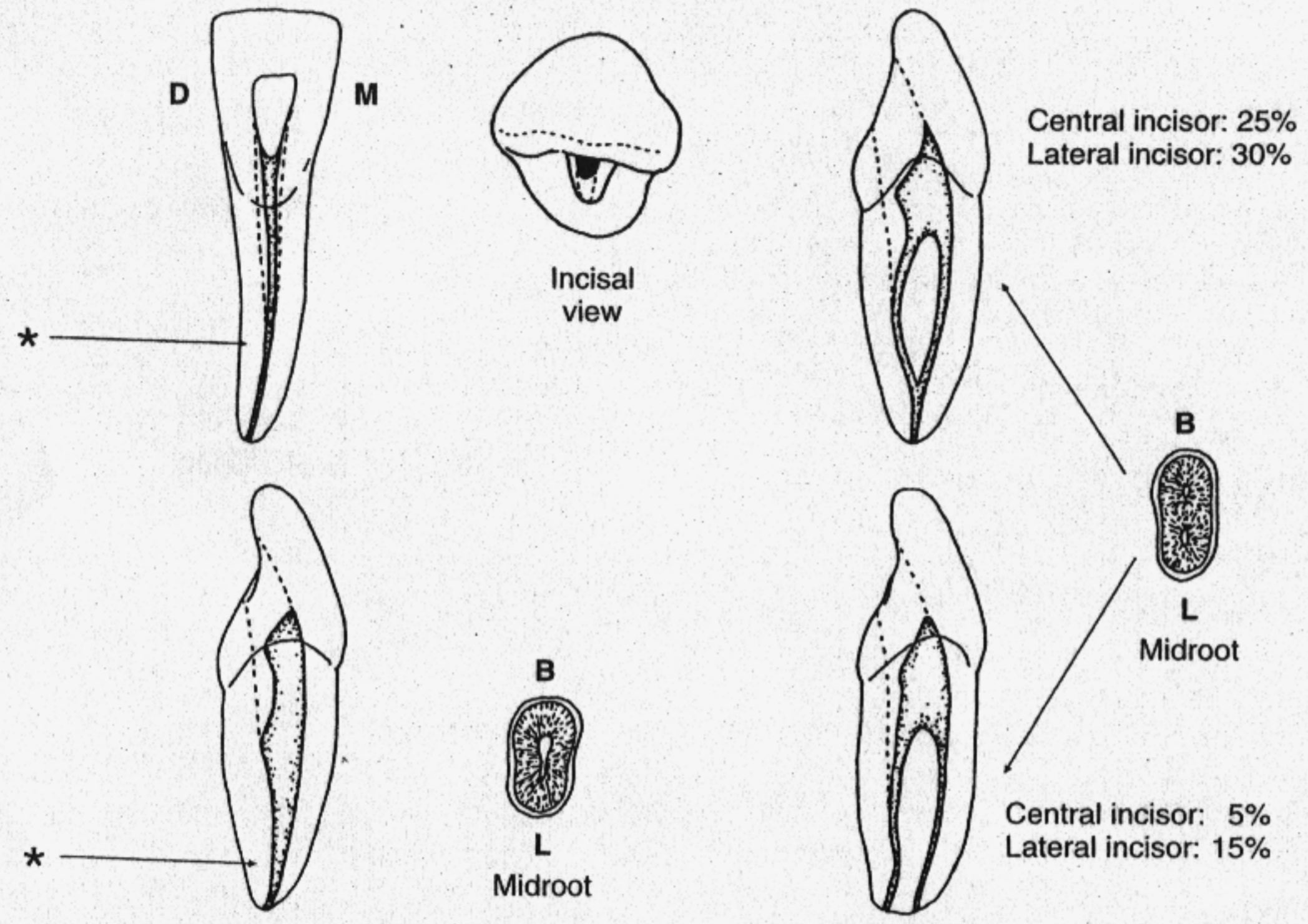
Maxillary Right Second Molar



Maxillary Right Second Molar

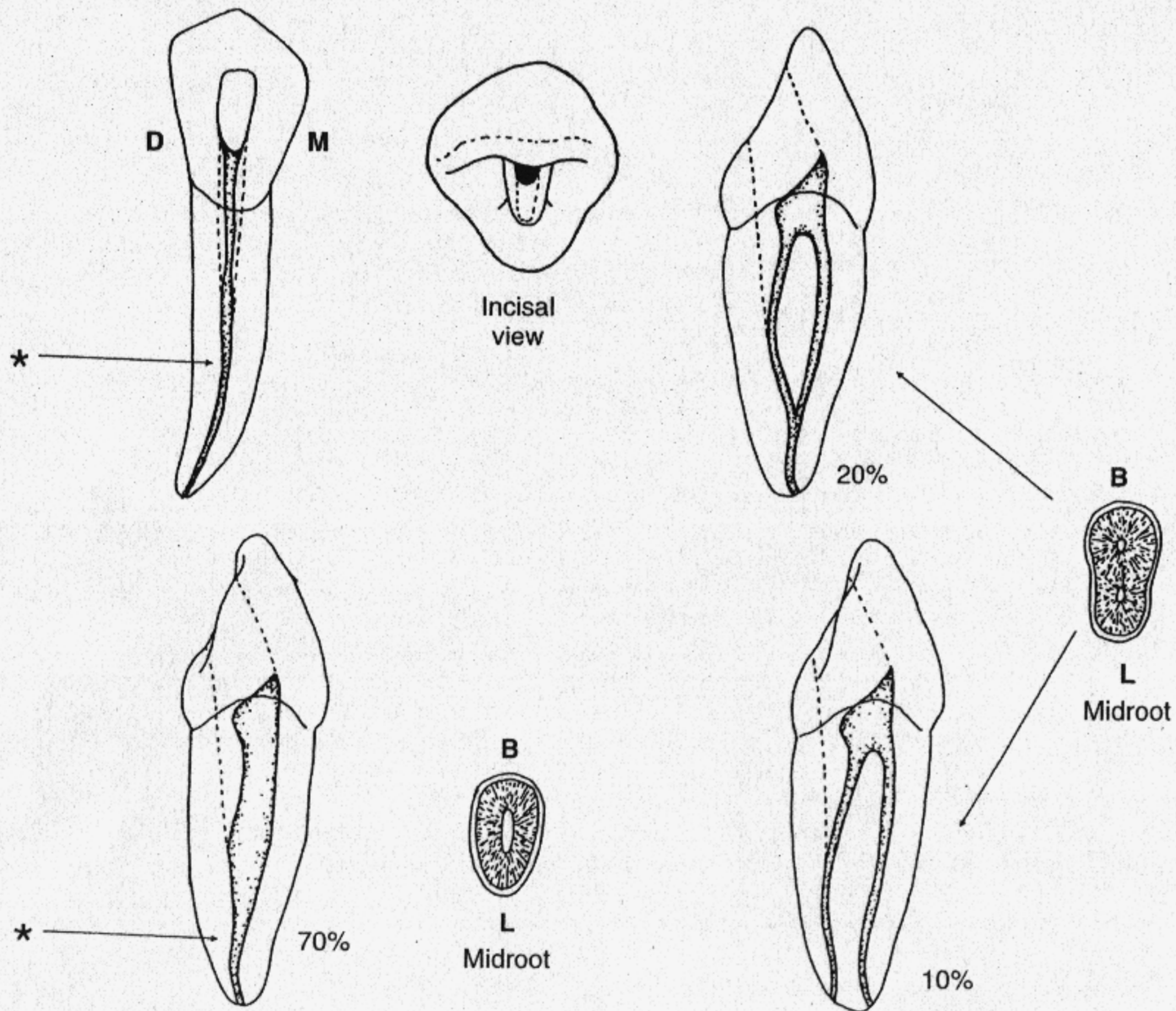


Mandibular Right Central and Lateral Incisor



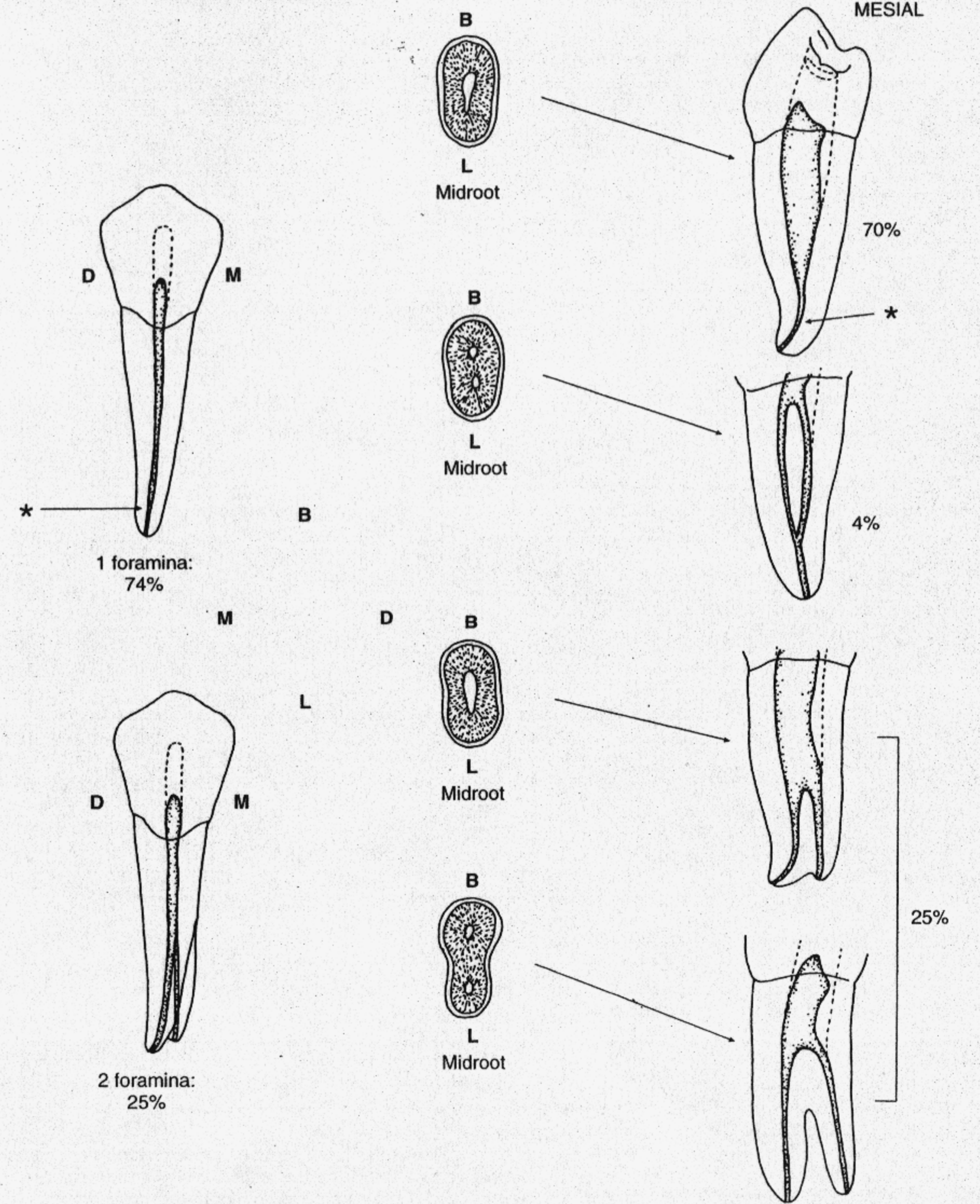
*Most common root curvatures

Mandibular Right Canine



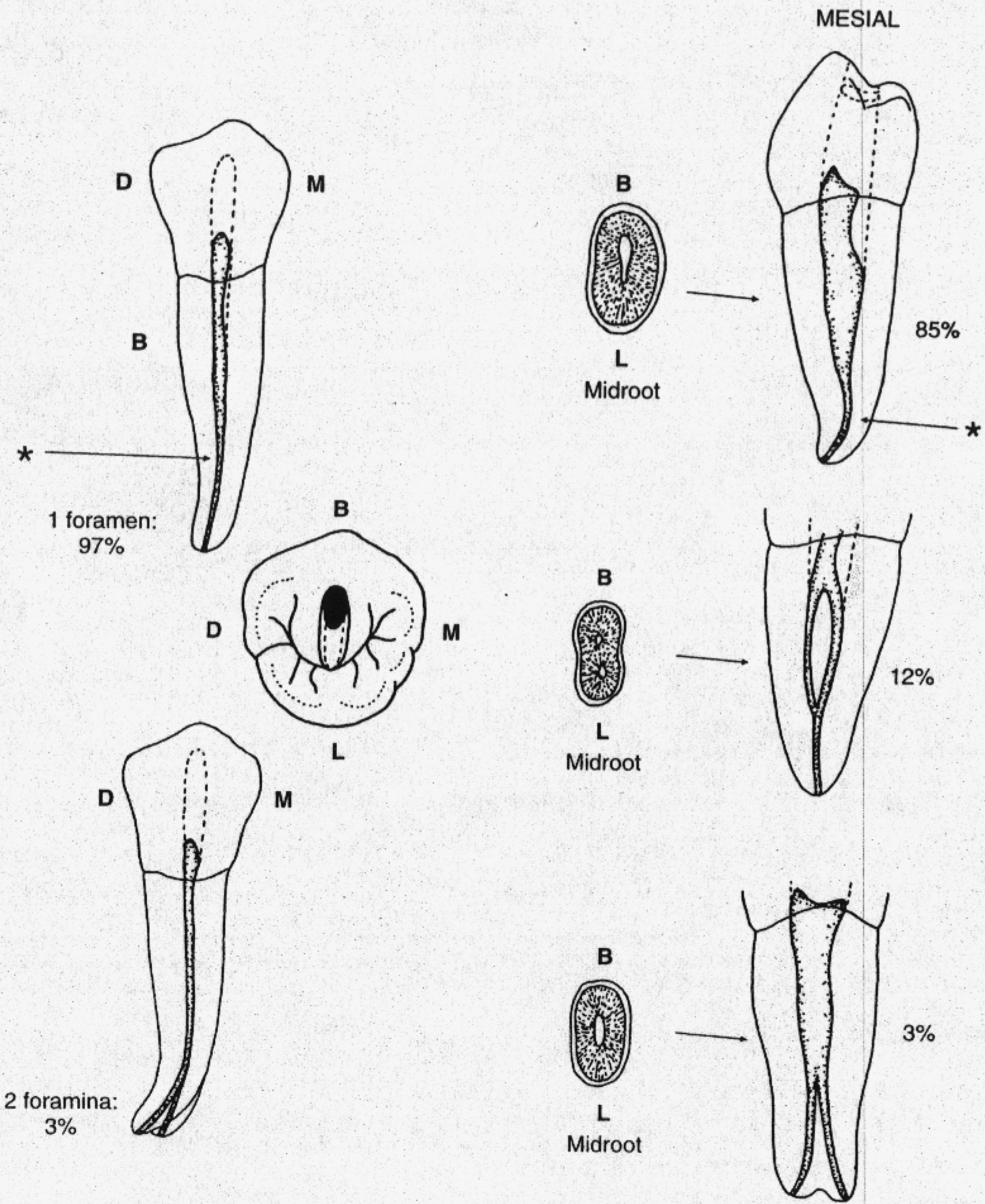
*Most common root curvatures

Mandibular Right First Premolar



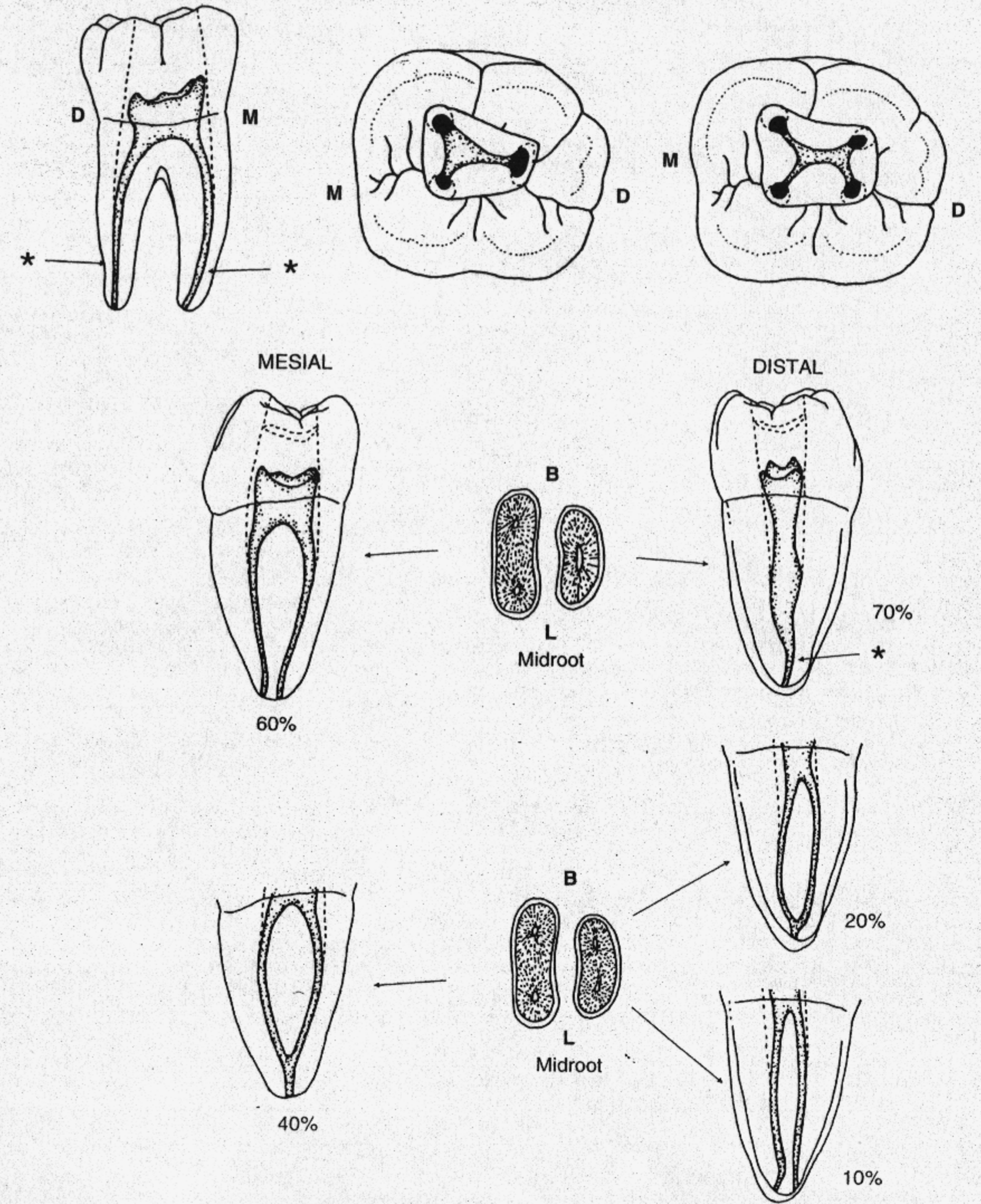
*Most common root curvatures

Mandibular Right Second Premolar



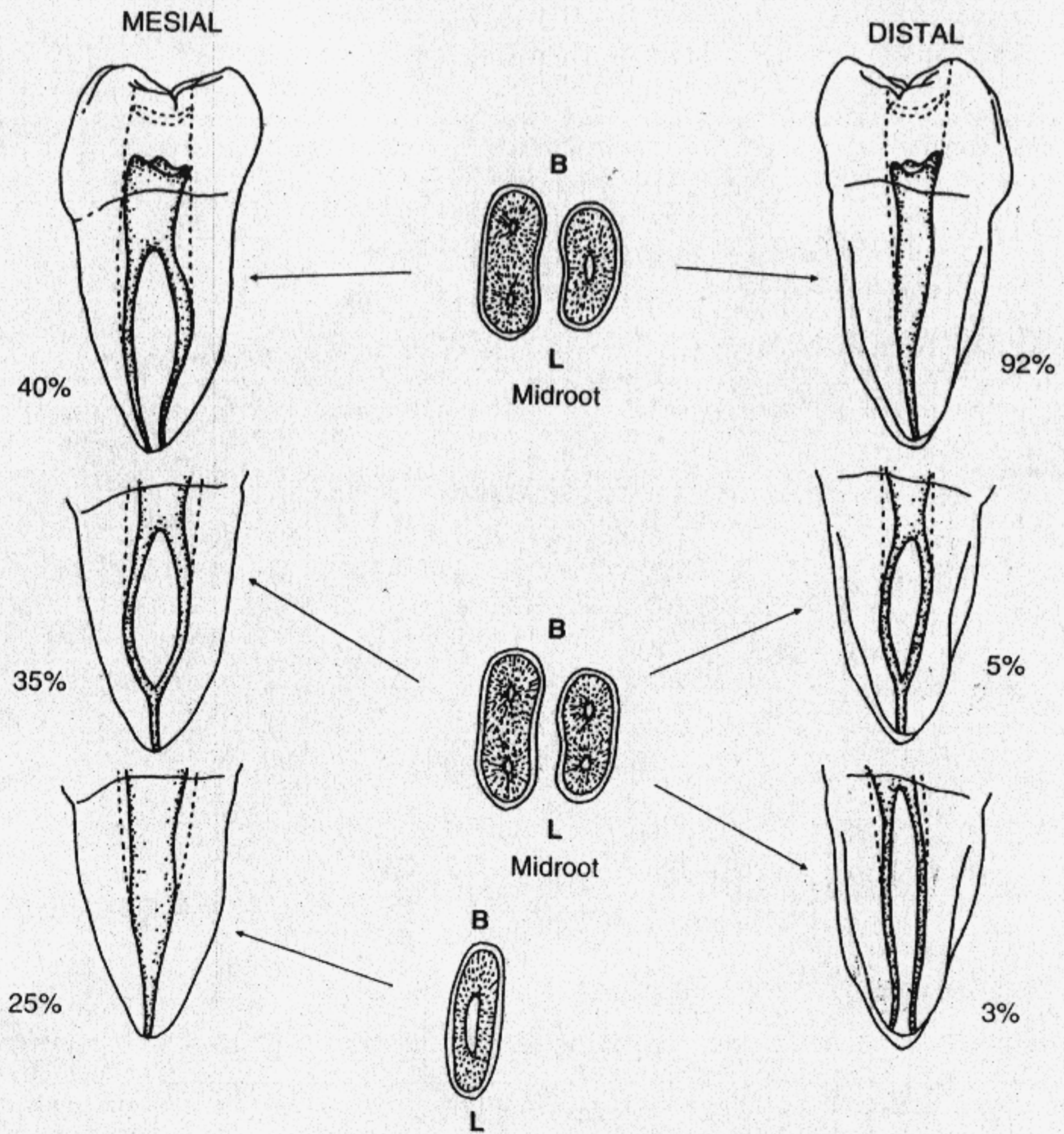
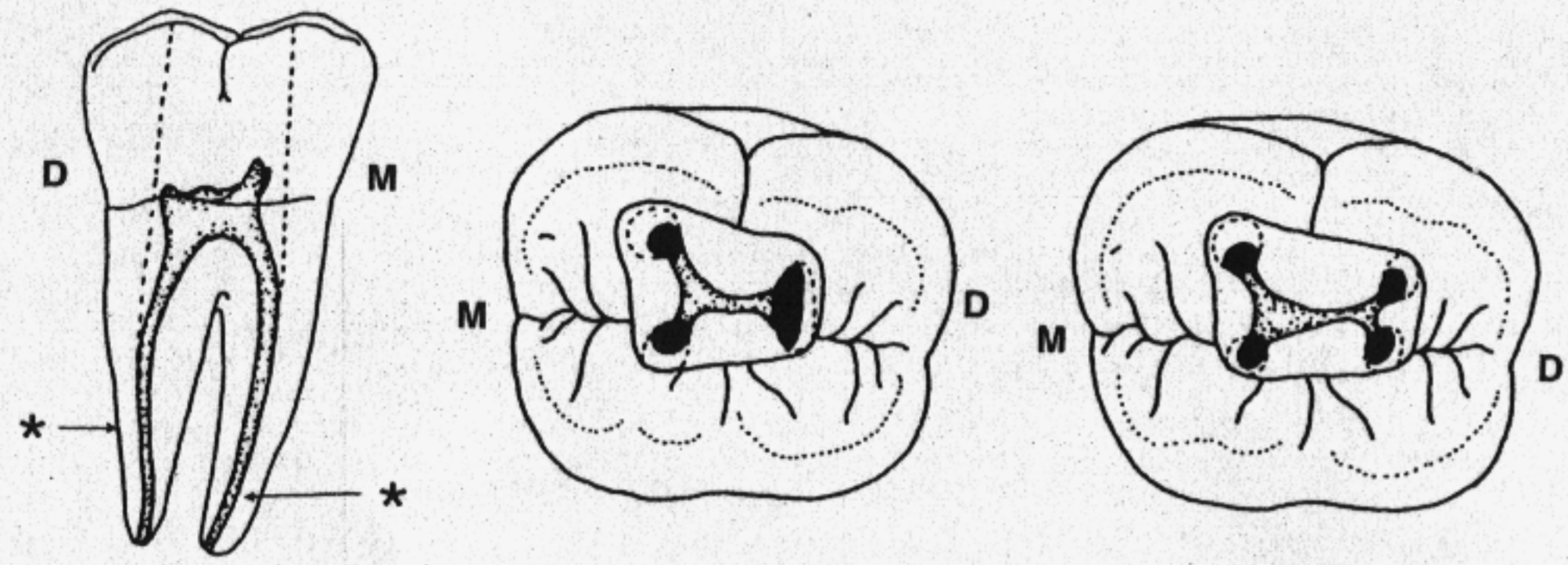
*Most common root curvatures

Mandibular Right First Molar



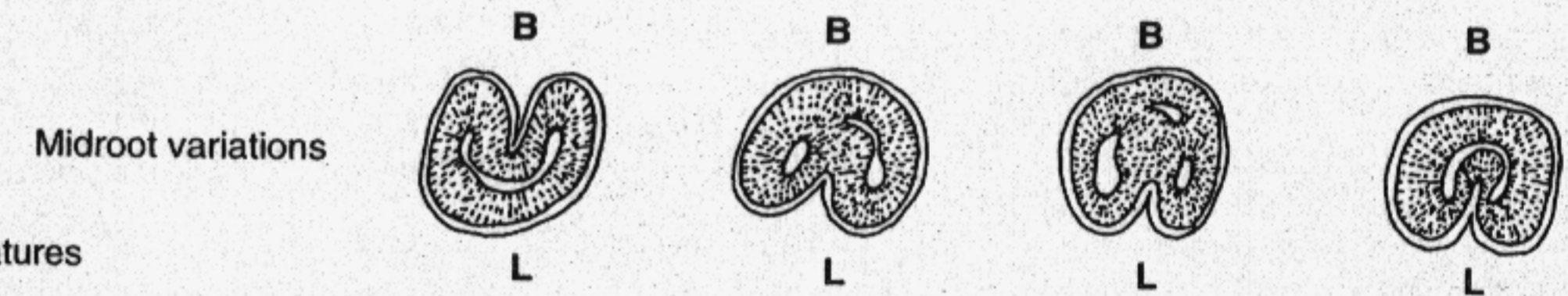
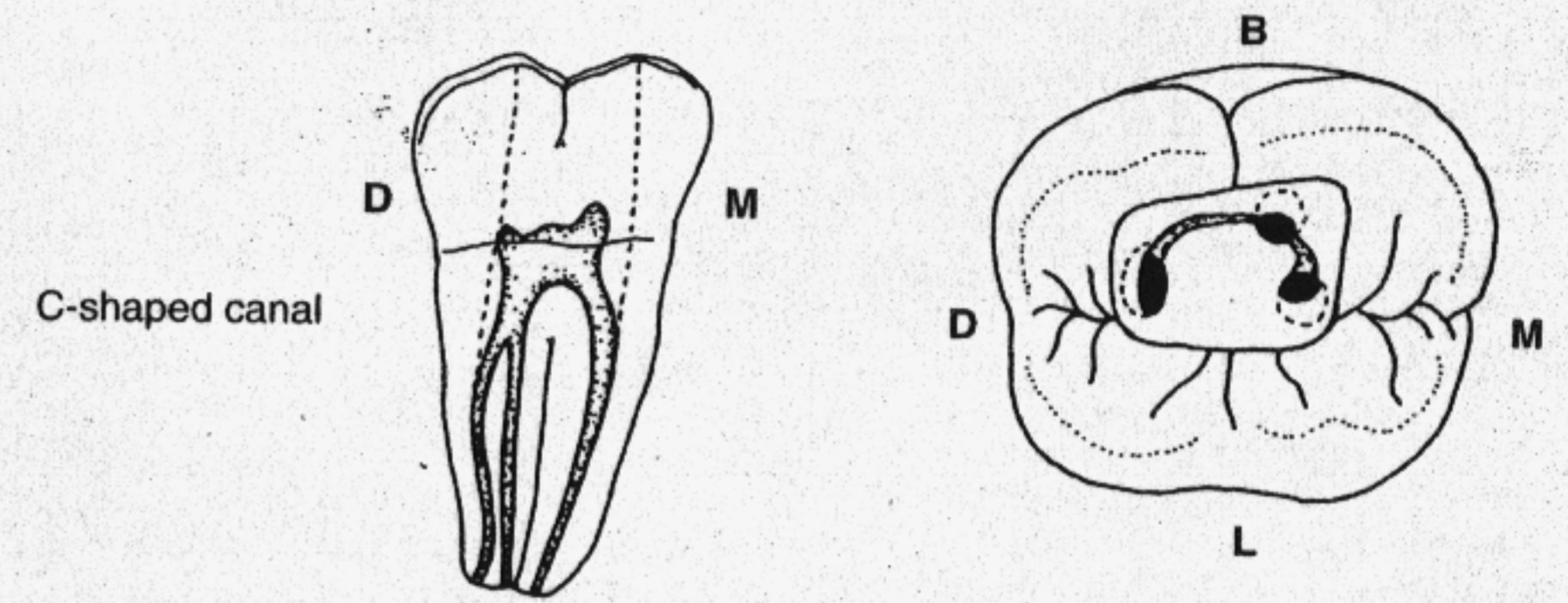
*Most common root curvatures

Mandibular Right Second Molar



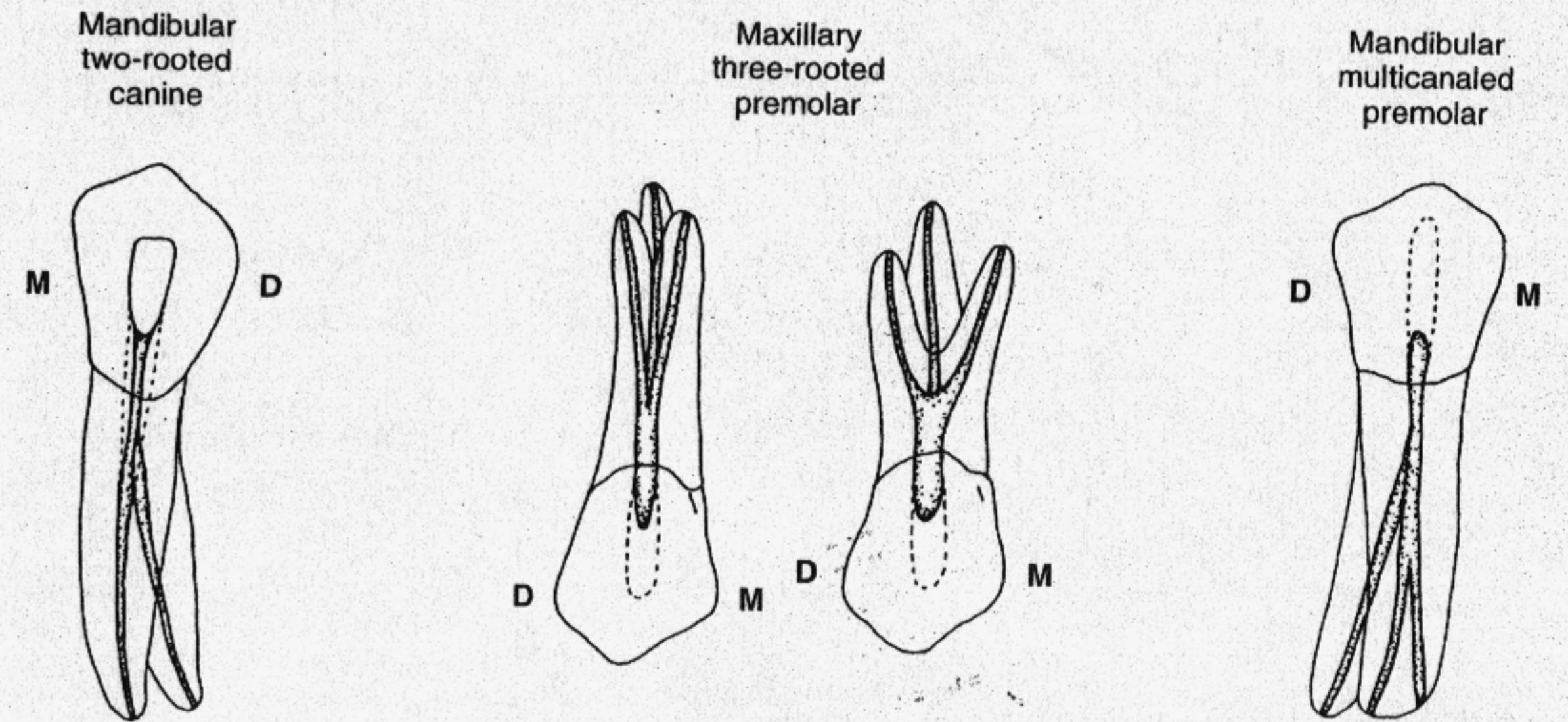
*Most common root curvatures

Mandibular Right Second Molar



*Most common root curvatures

Some Uncommon Variations



Mandibular three-rooted molar

Maxillary four-rooted second molar

